

## SMALL EPIDURAL HEMATOMA FOR SURGERY

S.A. Elenany

Mansoura University; Elgomhouria St., Mansoura 35516, Egypt

Contact: Sherief Ahmed Elenany dr. sherief89ahmed@gmail.com, sherief.elenany@suezuni.edu.eg

**Introduction.** Epidural hematoma (EDH) is when bleeding occurs between the tough outer membrane covering the brain (dura mater) and the skull. The most common cause is typically head injury. Diagnosis is typically by a computed tomography (CT) scan or magnetic resonance imaging. If large EDH, treatment is generally by urgent surgery in the form of a craniotomy or burr hole. Without treatment, death typically results.

We explore a surgical case of small frontal EDH in patient with Glasgow Coma Score 8.

**Case report.** Thirty years male patient was admitted at Emergency Hospital with Glasgow Coma Score 8 on ventilator. Rapid CT brain was done and showed massive brain edema with small EDH. Conservative treatment had been tried for 24 hours, but with no improvement as we could not give mannitol therapy to this patient. Follow-up CT showed the same EDH and brain edema. We tried new policy and evacuated EDH with giving mannitol and furosemide therapy postoperative. The patient became with Glasgow Coma Score 13 and improved in 7 days.

**Conclusion.** Evacuation of small EDH may be helpful in some conditions not responding to conservative treatment especially in severe brain edema.

**Key words:** epidural hematoma, brain edema, disturbed conscious level

**For citation:** Elenany S.A. Small epidural hematoma for surgery. Neyrokhirurgiya = Russian Journal of Neurosurgery 2020;22(3):57–9.

DOI: 10.17650/1683-3295-2020-22-3-57-59



## Хирургическое лечение небольшой эпидуральной гематомы

Ш.А. Еленани

Университет Эль-Мансура; Египет, 35516 Эль-Мансура, ул. Эль-Гомурия

**Введение.** Эпидуральная гематома (ЭГ) возникает в результате кровоизлияния в пространство между твердой мозговой оболочкой и черепом. Наиболее распространенной причиной такого кровоизлияния, как правило, является черепно-мозговая травма. Диагноз обычно ставят с помощью компьютерной (КТ) или магнитно-резонансной томографии. При большом размере ЭГ показано неотложное хирургическое вмешательство (краниотомия или наложение фрезевого отверстия). При отсутствии лечения велика вероятность летального исхода.

Мы представляем клинический случай хирургического лечения небольшой ЭГ у пациента с нарушением сознания, соответствующим 8 баллам по шкале комы Глазго.

**Клиническое наблюдение.** Пациент 30 лет был доставлен в больницу скорой медицинской помощи с нарушением сознания, оцененным в 8 баллов по шкале комы Глазго, и с нарушением дыхания, потребовавшим искусственной вентиляции легких. При срочной КТ выявлен массивный отек головного мозга и небольших размеров ЭГ. Консервативное лечение в течение 24 ч не привело к улучшению состояния пациента. Следующая КТ также показала отсутствие улучшения. Ввиду этого было принято решение об удалении ЭГ хирургическим путем, после чего была назначена противоотечная терапия маннитолом и фуросемидом. После этого уровень сознания восстановился до 13 баллов по шкале комы Глазго, состояние пациента улучшилось через 7 дней.

**Заключение.** Эвакуация небольших ЭГ может быть полезна при некоторых состояниях, не поддающихся консервативному лечению, например при отеке головного мозга.

**Ключевые слова:** эпидуральная гематома, отек головного мозга, нарушение сознания

**Для цитирования:** Еленани Ш.А. Хирургическое лечение небольшой эпидуральной гематомы. Нейрохирургия 2020;22(3):57–9. (На англ.).

## INTRODUCTION

An epidural hematoma (EDH) is an extra-axial collection of blood within the potential space between the outer layer of the dura mater and the inner table of the skull. It is

confined by the lateral sutures (especially the coronal sutures) where the dura inserts. It is a life-threatening condition, which may require immediate intervention and can be associated with significant morbidity and mortality if left

untreated. Rapid diagnosis and evacuation are important for a good outcome [1]. It occurs in approximately 10 % of traumatic brain injuries requiring hospitalization. Both by traumatic and non-traumatic mechanisms can cause an EDH. The majority of cases related to a traumatic mechanism are a result of head injury due to motor vehicle collisions, physical assaults, or accidental falls [2, 3].

Non-traumatic mechanisms include the following: infection/abscess, coagulopathy, hemorrhagic tumors, vascular malformation.

An EDH occurs in 2 % of all head injuries and up to 15 % of all fatal head traumas. Males are more often affected than are females. Furthermore, the incidence is higher among adolescents and young adults. The mean age of affected patients is 20 to 30 years, and it is rare after 50 to 60 years of age. As an individual's age advances, the dura mater becomes more adherent to the overlying bone. This decreases the chance that a hematoma can develop in the space between the cranium and dura [4, 5].

**Pathophysiology.** Most EDHs result from arterial bleeding from a branch of the middle meningeal artery. The anterior meningeal artery or dural arteriovenous fistula at the vertex may be involved [6, 7]. Up to 10 % of EDHs are due to venous bleeding following the laceration of a dural venous sinus. In adults, up to 75 % of EDHs occur in the temporal region. However, in children, they occur with similar frequency in the temporal, occipital, frontal, and posterior fossa regions [8]. A skull fracture is present in the majority of patients with EDH. These hematomas often present beneath a fracture of the squamous part of the temporal bone [9]. Based on radiographic progression, it can be classified into one of the following [10, 11]:

- type I: acute; occurs on day 1 and associated with a “swirl” of un-clotted blood;
- type II: subacute occurring between days 2 to 4 and usually solid;
- type III: chronic occurring between days 7 to 20; mixed or lucent appearance with contrast enhancement.

Epidural hematoma is a neurosurgical emergency. It, therefore, requires urgent surgical evacuation to prevent irreversible neurological injury and death secondary to hematoma expansion and herniation [12]. Surgical intervention is recommended in patients with [13]:

- acute EDH;
- hematoma volume  $\geq 30$  ml regardless of Glasgow Coma Score (GCS);
- GCS  $\leq 9$  with pupillary abnormalities like anisocoria.

**Operative management.** In patients with acute and symptomatic EDHs, the treatment is craniotomy and hematoma evacuation [14].

**Non-operative management.** There is a scarcity of literature comparing conservative management with surgical intervention in patients with EDH. However, a non-surgical approach may be considered in a patient with acute EDH who has mild symptoms and meets all of the criteria listed below:

- EDH volume  $< 30$  ml;
- clot diameter  $< 15$  mm;
- midline shift  $< 5$  mm;
- GCS  $> 8$  and on physical examination, shows no focal neurological symptoms [15].

We explore a surgical case of small frontal EDH in patient with Glasgow Coma Score 8.

### CASE REPORT

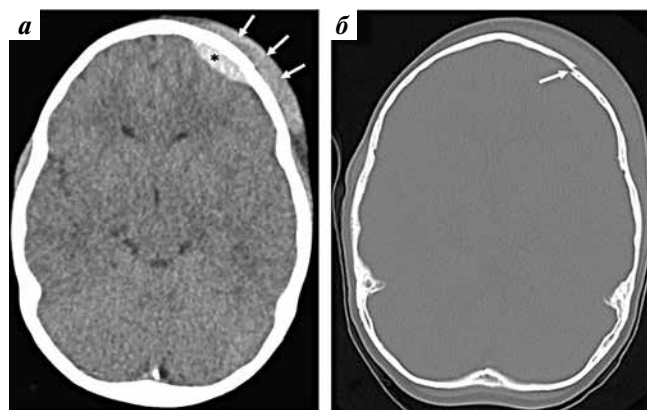
Thirty years male patient was admitted at Emergency Hospital with GCS 8 on ventilator. Rapid computed tomography brain was done and showed massive brain edema with left frontal small EDH (fig. 1). Conservative treatment had been tried for 24 hours, but with no improvement as we could not give mannitol therapy to this patient. Follow up computed tomography showed the same EDH and brain edema. Laboratory studies such as international normalized ratio, partial thromboplastin time, thromboplastin time, and liver function test were obtained to assess for increased bleeding risk or underlying coagulopathies

We tried new policy and evacuated EDH with giving mannitol and furosemide therapy postoperative. The patient became with GCS 13 and improved in 7 days.

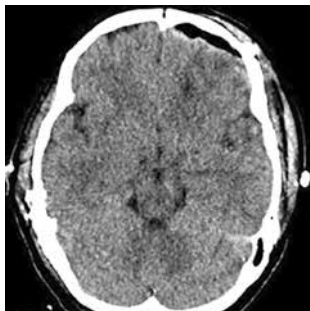
After general anesthesia, a left pterional approach was done then a craniotomy with four burr holes. Elevation of bone flap. The EDH was evacuated (fig. 2) and the bone was repositioned with closure of skin.

### DISCUSSION

Mannitol is an osmotic diuretic, so we use it to decrease intracranial pressure. Its usage is contraindicated in cases of EDH. In our case, there is two problems. First, left frontal EDH which we cannot use mannitol with; second, severe brain edema that can be decreased by usage of mannitol. So we tried the conservative treatment. We see that if conservative treatment is continued, brain edema may not decrease and the patient may die. Finally, we tried new policy, evacuated the EDH and give mannitol freely. The patient is fully conscious.



**Fig. 1.** Pre-operative computed tomography brain explaining: a – left small epidural hematoma (asterisk) with severe brain edema (arrows); b – left frontal bone fracture



**Fig. 2.** Post-operative computed tomography brain explaining epidural hematoma evacuation

## CONCLUSION

Epidural hematoma is a relatively common presentation to the emergency department, and if not diagnosed is associated with a high mortality. The condition is best managed by a multidisciplinary team that includes the emergency room physician, the trauma team, radiologist, neurologist, neurosurgeon, intensivist and the intensive care unit nurses. The condition has been associated with mortality rates in excess of 15 %.

Evacuation of small EDH may be helpful in some conditions not responding to conservative treatment especially in severe brain edema.

## ЛИТЕРАТУРА / REFERENCES

- Rosenthal A.A., Solomon R.J., Eyerly-Webb S.A. et al. Traumatic epidural hematoma: patient characteristics and management. *Am Surg* 2017;83(11):e438–40.
- Babu J.M., Patel S.A., Palumbo M.A., Daniels A.H. Spinal emergencies in primary care practice. *Am J Med* 2019;132(3):300–6. DOI: 10.1016/j.amjmed.2018.09.022.
- Kanematsu R., Hanakita J., Takahashi T. et al. Radiologic features and clinical course of chronic spinal epidural hematoma: report of 4 cases and literature review. *World Neurosurg* 2018;120:82–9. DOI: 10.1016/j.wneu.2018.08.058.
- Tamburrelli F.C., Meluzio M.C., Masci G. et al. Etiopathogenesis of traumatic spinal epidural hematoma. *Neurospine* 2018;15(1):101–7. DOI: 10.14245/ns.1834938.469.
- Fernández-Abinader J.A., González-Colón K., Feliciano C.E., Mosquera-Soler A.M. Traumatic brain injury profile of an elderly population in Puerto Rico. *P R Health Sci J* 2017;36(4):237–9.
- Chicote Álvarez E., González Castro A., Ortiz Lasa M. et al. Epidemiology of traumatic brain injury in the elderly over a 25 year period. *Rev Esp Anestesiol Reanim* 2018;65(10):546–51. DOI: 10.1016/j.redar.2018.06.003.
- Burjorjee J.E., Rooney R., Jaeger M. Epidural hematoma following cessation of a direct oral anticoagulant: a case report. *Reg Anesth Pain Med* 2018;43(3):313–6. DOI: 10.1097/AAP.0000000000000738.
- Bonow R.H., Barber J., Temkin N.R. et al. The outcome of severe traumatic brain injury in Latin America. *World Neurosurg* 2018;111:e82–90. DOI: 10.1016/j.wneu.2017.11.171.
- Flaherty B.F., Moore H.E., Riva-Cambrin J., Bratton S.L. Repeat head CT for expectant management of traumatic epidural hematoma. *Pediatrics* 2018;142(3):e20180385. DOI: 10.1542/peds.2018-0385.
- Bhorkar N.M., Dhansura T.S., Tarawade U.B., Mehta S.S. Epidural hematoma: vigilance beyond guidelines. *Indian J Crit Care Med* 2018;22(7):555–7. DOI: 10.4103/ijccm.IJCCM\_71\_18.
- Gutowski P., Meier U., Rohde V. et al. Clinical outcome of epidural hematoma treated surgically in the era of modern resuscitation and trauma care. *World Neurosurg* 2018;118:e166–74. DOI: 10.1016/j.wneu.2018.06.147.
- Basamh M., Robert A., Lamoureux J. et al. Epidural hematoma treated conservatively: when to expect the worst. *Can J Neurol Sci* 2016;43(1):74–81. DOI: 10.1017/cjn.2015.232.
- Aguilar M.I., Brott T.G. Update in intracerebral hemorrhage. *Neurohospitalist* 2011;1(3):148–59. DOI: 10.1177/1941875211409050.
- Jeong Y.H., Oh J.W., Cho S. Clinical outcome of acute epidural hematoma in Korea: preliminary report of 285 cases registered in the Korean Trauma Data Bank System. *Korean J Neurotrauma* 2016;12(2):47–54. DOI: 10.13004/kjnt.2016.12.2.47.
- Guo C., Liu L., Wang B., Wang Z. Swirl sign in traumatic acute epidural hematoma: prognostic value and surgical management. *Neurol Sci* 2017;38(12):2111–6. DOI: 10.1007/s10072-017-3121-4.

### Authors' contribution

S.A. Elenany performed all of the procedures, clinical assessment, follow-up of patient, collection of results and is responsible for the article text.

Вклад авторов

Ш.А. Еленани провел все процедуры, клиническое обследование, наблюдение за пациентом, сбор результатов и несет ответственность за содержание статьи.

### ORCID of authors / ORCID авторов

S.A. Elenany / Ш.А. Еленани: <https://orcid.org/0000-0001-7392-3656>

### Conflict of interest. The author declares no conflict of interest.

Конфликт интересов. Автор заявляет об отсутствии конфликта интересов.

### Financing. The study was performed without external funding.

Финансирование. Исследование проведено без спонсорской поддержки.

### Informed consent. The patient gave written informed consent to participate in the study.

Информированное согласие. Пациент подписал информированное согласие на участие в исследовании.

Статья поступила: 13.01.2020. Принята к публикации: 16.06.2020.

Article submitted: 13.01.2020. Accepted for publication: 16.06.2020.