

DOI: <https://doi.org/10.63769/1683-3295-2026-28-1-80-88>

Frontal mucocele with extension to the skull base

Case report and review of the literature

Contacts:Gino Vasquez-Paredes
ginovasquez85@gmail.com

G. Vasquez-Paredes

*School of Medicine, Antenor Orrego Private University; Trujillo, 13007, Peru;
Neurosurgery Department, Belen Hospital of Trujillo; 13007, Peru*

Background. Mucoceles are benign pseudocysts with mucous content in the paranasal sinuses that can expand, destroying bone and invading adjacent structures.

Case report. A 69-year-old female patient presented with an initially painless tumor in the left frontal region 5 years ago, which progressively increased in volume, causing frontal pain and difficulty opening the eyelid. Physical examination revealed a 6 × 5 cm rounded tumor in the left supraciliary region. A mucocele of the left frontal sinus with the erosion of the table was diagnosed, and the patient underwent surgery, performing a bi-coronal incision, total excision of the mucocele, cranialization of the left frontal sinus, and cranioplasty with titanium mesh and self-drilling screws.

Discussion. The formation of mucoceles is of variable etiology; the most frequent location is at the frontal level, which can erode the internal table of the frontal sinus, producing invasion towards the dura mater and, in some cases, the brain parenchyma, causing infections. The clinical picture is variable and depends on the location. Surgical management should be focused on optimizing a definitive resolution of the symptoms, maintaining an anatomy with normal drainage of the paranasal sinuses, and preventing the risk of recurrence.

Conclusion. Mucoceles constitute a benign pathology. However, they should be treated immediately through a surgical approach, preferably with an open approach that allows direct access to the frontal sinus, adequate removal of the mucocele, and complete obliteration to prevent the risk of infections or recurrence.

Keywords: mucocele, frontal sinus, frontal bone, case reports

For citation: Vasquez-Paredes G. Frontal mucocele with extension to the skull base. Case report and review of the literature. *Neyrokhirurgiya = Russian Journal of Neurosurgery* 2026;28(1):80–8.

DOI: <https://doi.org/10.63769/1683-3295-2026-28-1-80-88>

Мукоцеле лобной пазухи с разрастанием к основанию черепа. Описание случая и обзор литературы

G. Vasquez-Paredes

*Школа медицины, Частный университет Антенор Оррего; Перу, 13007 Трухильо;
Отделение нейрохирургии, Больница «Белен» города Трухильо; Перу, 13007 Трухильо***Контакты:** Gino Vasquez-Paredes ginovasquez85@gmail.com

Введение. Мукоцеле – это доброкачественные псевдокисты со слизистым содержимым в околоносовых пазухах, которые могут расширяться, разрушая кость и проникая в соседние структуры.

Описание случая. Пациентка, 69 лет, обратилась с изначально безболезненной опухолью в левой лобной области 5 лет назад. Опухоль постепенно увеличивалась в объеме, вызывая боль в лобной области и затруднение при открывании века. При физикальном обследовании обнаружена округлая опухоль размером 6 × 5 см в левой супрацилиарной области. Была диагностирована мукоцеле левой лобной пазухи с эрозией пластинки, и пациентке проведена операция, в ходе которой выполнены бикоронарный разрез, полное иссечение мукоцеле, краниализация левой лобной пазухи и краниопластика с помощью титановой сетки и самосверлящих винтов.

Обсуждение. Формирование мукоцеле имеет различную этиологию; наиболее частое расположение – на лобном уровне, что может привести к эрозии внутренней пластинки лобной пазухи, вызывая инвазию в твердую мозговую оболочку и, в некоторых

случаях, в паренхиме мозга, вызывая инфекции. Клиническая картина варьирует и зависит от локализации. Хирургическое лечение должно быть сосредоточено на оптимизации окончательного разрешения симптомов, поддержании анатомии с нормальным дренажем околоносовых пазух и предотвращении риска рецидива.

Заключение. Мукоцеле представляют собой доброкачественную патологию. Однако их следует лечить немедленно хирургически, предпочтительно открытым подходом, который обеспечивает прямой доступ к лобной пазухе, адекватное удаление мукоцеле и полную облитерацию, чтобы предотвратить риск инфекций или рецидива.

Ключевые слова: мукоцеле, лобная пазуха, лобная кость, отчеты о случаях.

Для цитирования: Vasquez-Paredes G. Мукоцеле лобной пазухи с разрастанием к основанию черепа. Описание случая и обзор литературы. Нейрохирургия 2026;28(1):80–8.

DOI: <https://doi.org/10.63769/1683-3295-2026-28-1-80-88>

BACKGROUND

Mucoceles are benign, slow-growing pseudocysts with mucous content, with pseudostratified columnar epithelial lining and, in some cases, the squamous epithelium [1] located in the paranasal sinuses [2, 3], which can expand by causing demineralization and eroding the intraorbital and intracranial bone [4]. The cause may be secondary to an obstruction of the sinus ostium with chronic overproduction of mucus, a sinus fracture with subsequent nasosinus infection or surgical procedures, allergies, or tumors [5, 6]. They are most frequently located in the frontal and ethmoid sinuses, followed by the maxillary sinuses and rarely the sphenoid sinuses [3, 7]. They are predominantly unilateral, although they can also be bilateral.

Mucoceles occur primarily in adult patients between 40–70 years of age [7], have no predilection for sex, and less frequently affect children [3]. Symptoms and signs depend on the location, but generally, frontal mucoceles are associated with local pain, erythema, headache, exophthalmos, and blurred vision that can lead to blindness

[3, 8]. In other cases, there may be osteomyelitis, cellulitis, and abscesses, and if there is an invasion of the frontal bone with bone destruction, they can cause meningitis or brain abscesses [6].

Treatment is surgical, and it can range from open surgery to an endoscopic endonasal approach. In both cases, the main objective is completely draining the compromised sinus and relieving the patient's symptoms [3]. Despite successful management, complications exist, such as recurrence in 8.2 % of cases of open surgery and 3.5 % in the endoscopic approach [9].

CLINICAL CASE

A 69-year-old female patient presented a painless tumor in the left frontal region 5 years ago, which increased in volume. In the last year, she had frontal pain and had difficulty opening her left eyelid, which is why she went to the neurosurgery outpatient clinic. She did not present symptoms of nasal pathology, allergies, or surgical history. On physical examination, she presented a 6 × 5 cm rounded tumor

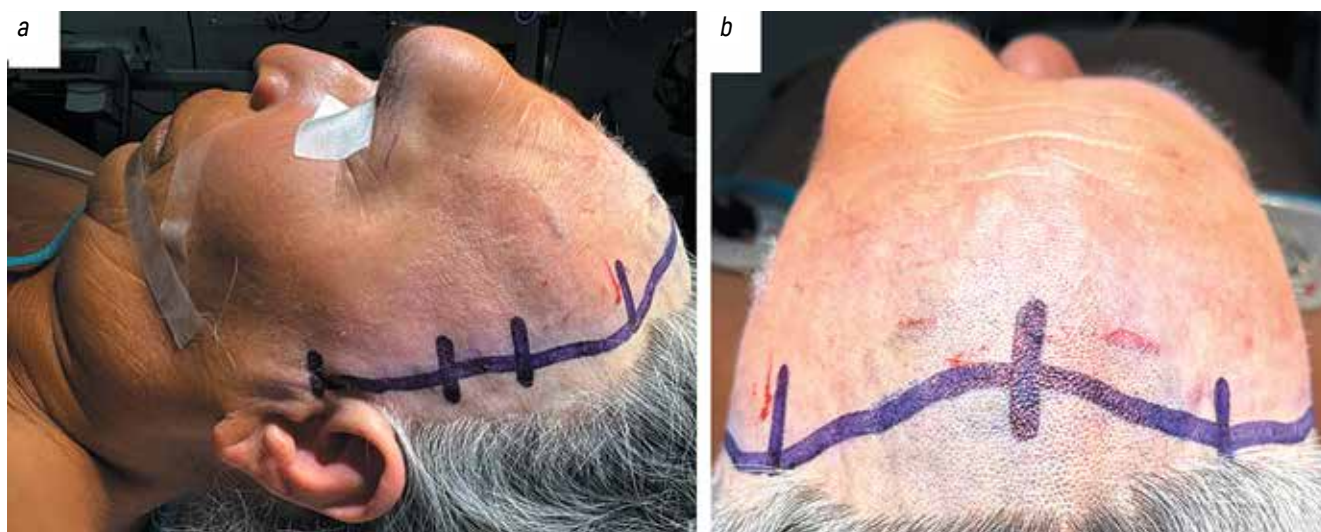


Fig. 1. Images showing a left frontal tumor with increased volume causing deformity. In addition, the marking in the frontal region of the bi-coronal surgical access can be seen in the sagittal view (a) and posterior view (b)

Рис. 1. Вызывающая деформацию опухоль в лобной области слева увеличенного объема. В лобной области видна разметка бикоронарного хирургического доступа в сагиттальной (a) и задней (b) проекциях

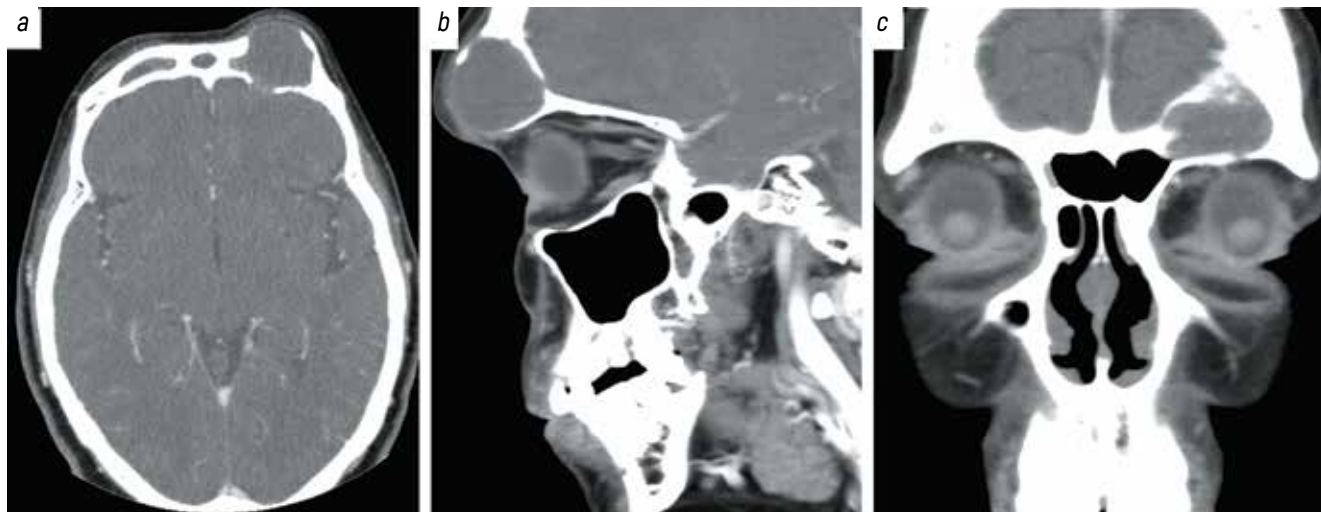


Fig. 2. Contrast-enhanced brain CT scan showing a left frontal lesion eroding the internal table of the ipsilateral frontal sinus in axial view (a), sagittal view (b), and coronal view (c)

Рис. 2. Компьютерная томография головного мозга с контрастным усилением, демонстрирующая опухоль в левой лобной области, разрушающую внутреннюю пластинку ипсилатеральной пазухи: аксиальная (a), сагиттальная (b) и корональная (c) проекции

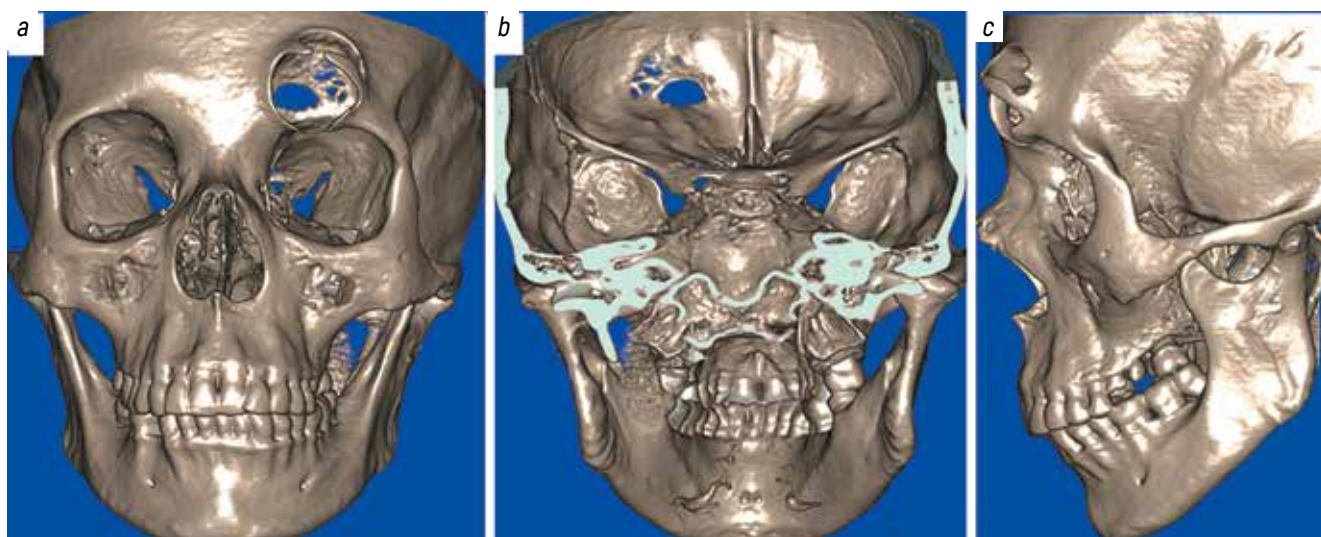


Fig. 3. Computed tomography of the facial massif with 3D reconstruction showing the expanded left frontal sinus with remodeling and adjacent bone destruction in anterior view (a), posterior view (b), and sagittal view (c)

Рис. 3. Компьютерная томография лицевого образования с 3D-реконструкцией демонстрирует расширение левой лобной пазухи с ремоделированием кости и участками прилежащего костного разрушения: а – передняя проекция; б – задняя проекция; с – сагиттальная проекция

on the left supraciliary, with defined edges, a complex, fixed consistency, and pain to pressure, which caused limitation for eyelid opening (Fig. 1). A 3D brain computed tomography (CT) with contrast and easy solid showed a space-occupying mass at the level of the left frontal sinus with adjacent bone destruction and polysinusopathy (Fig. 2, 3). Inflammatory serological markers were within normal ranges. The patient underwent surgery with a bicoronal incision, total excision of the mucocele, cranialization of the left frontal sinus, and cranioplasty with titanium mesh and self-drilling screws.

Procedure description. The patient was positioned supine, with the head in a straight line. A bi-coronal incision

was made, and the skin flap was retracted until the visible tumor was drained, obtaining 10 ccs of foul-smelling yellowish mucous secretion. The mucocele was excised entirely with subsequent cranialization of the left frontal sinus until the bone defect in the internal table was evident, checking the integrity of the dura mater. Subsequently, the hyperostotic bone tissue was removed with a metal curette, and bone wax with vancomycin powder was placed. A titanium mesh cranioplasty was performed, which was fixed to the bone edge with self-drilling titanium screws (Fig. 4). The patient did not present any complications in the postoperative period; the control brain CT without contrast showed adequate reconstruction and

elimination of the mucocele. She was discharged on the third day and attended a follow-up visit to the neurosurgery outpatient clinic. The surgical wound healed, and her cosmetic appearance improved (Fig. 5). The anatomopathological result confirmed the diagnosis, but the culture did not show bacterial growth on the third day.

DISCUSSION

Regarding the case, a search of the relevant literature on the current management of this pathology was carried out in the following databases: Medline via Pubmed, Scopus, and ScienceDirect. Boolean operators were used for the search using some keywords such as (“Mucocele”) or

(“Frontal sinus”) or (“Frontal bone”) or (“Case reports”). Articles of the case report or case series type published in English were included from 2020 to the present.

11 case reports were chosen from various countries. Of these, 72.72 % were male, the mean age was 42.72 years, and 2 cases belonged to the pediatric population. The main symptoms were headache, palpable mass, visual disturbances, and proptosis. All patients were treated surgically. The approaches varied, from surgical excision through a craniotomy to endoscopic approach and combined (Table 1).

Mucocele is a benign, slow-growing, often unilateral, mucous-filled pseudocystic lesion in the paranasal sinuses.

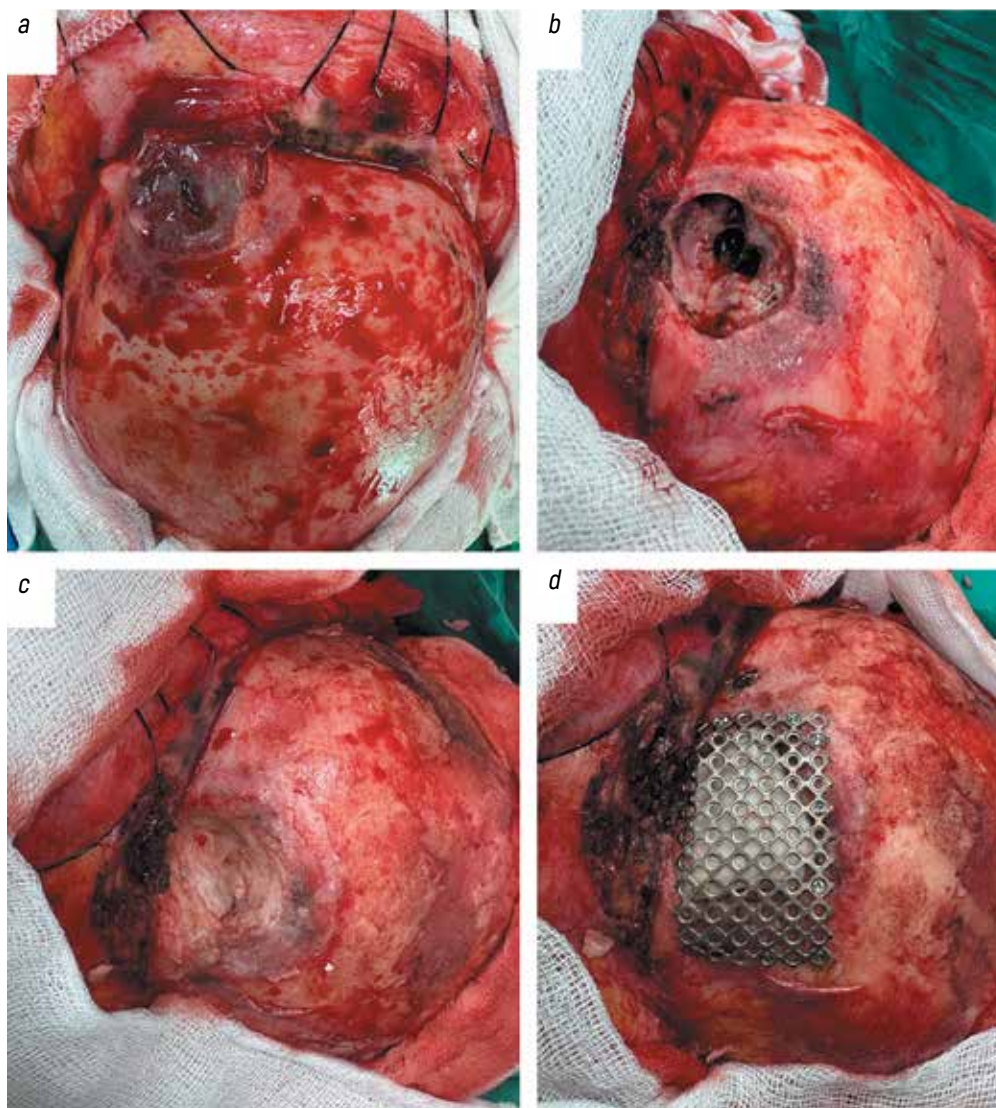


Fig. 4. Intraoperative images of the surgical access show the left frontal lesion with irregular edges, yellowish content, and a thin membrane [a]; after total resection of the mucocele and cranialization of the frontal sinus, erosion of the internal table of the left frontal sinus is evident [b], lining of the frontal sinus with bone wax mixed with vancomycin [c] and image after cranioplasty with titanium mesh and self-drilling screws [d]

Рис. 4. Интраоперационные изображения хирургического доступа показывают опухоль в лобной области слева с неровными краями, желтоватым содержимым и тонкой мембраной [a]. После тотальной резекции мукоцеле и краниализации лобной пазухи выявляется эрозия внутренней пластинки левой лобной пазухи [b]; выстилание лобной пазухи костным воском, смешанным с ванкомицином [c]; изображение после краниопластики титановым сетчатым имплантом и самосверлящими винтами [d]

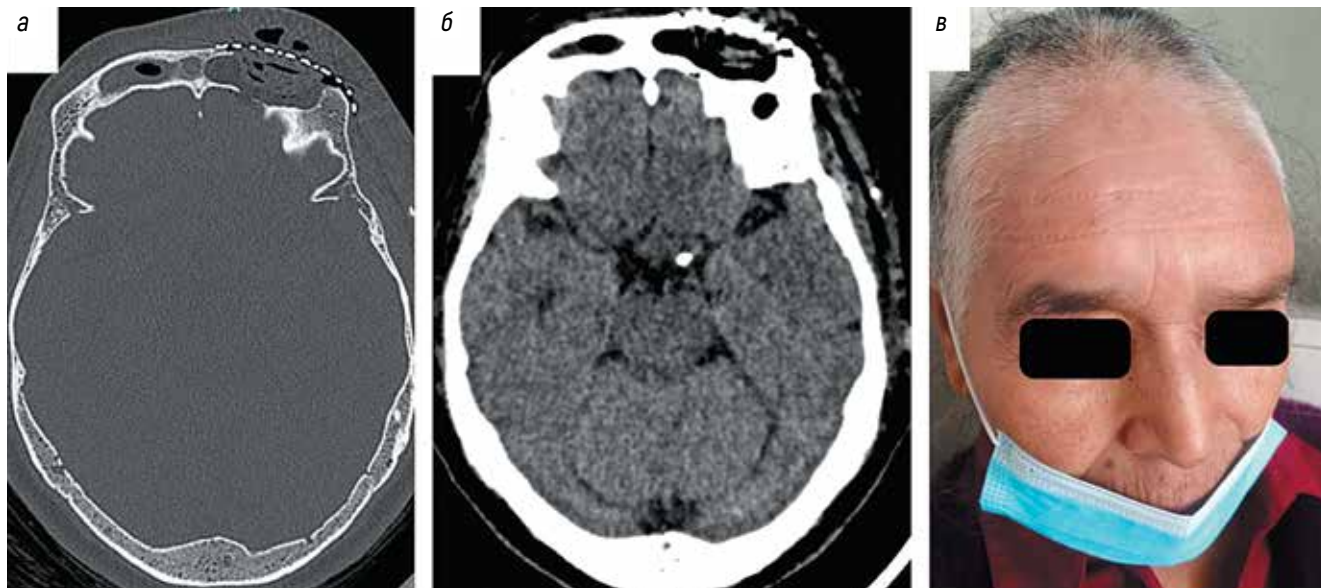


Fig. 5. Postoperative non-contrast brain CT scan showing adequate removal of the mucocele from the left frontal sinus and the titanium mesh in a view with a bone window (a), a view with a parenchymal window (b), and an image of the patient with evident improvement in facial aesthetics (c)

Рис. 5. Послеоперационная компьютерная томография головного мозга без контрастного усиления демонстрирует адекватное удаление мукоцеле из левой лобной пазухи и титановую сетку в режимах костного [a], и паренхиматозного окон [b]; c – изображение пациентки с очевидным улучшением лицевой эстетики

When the sinus ostium is obstructed, secretions accumulate, expanding the nasal cavity, causing erosion and reabsorption of the bone walls, and the mucocele can expand to neighboring structures [10, 11]. When the infection is chronic, it can cause a mucopiocele, an accumulation of pus in the paranasal sinus, generally due to *Staphylococcus aureus* and gram-negative bacilli [3, 12]. In addition, an immune component plays a role in bone resorption and expansion of mucoceles, such as prostaglandin E2, IL-1, and TNF [13], since they produce a constant synthesis of lymphocytes and monocytes that stimulate bone resorption and remodeling [14]. They can be primary when they appear de novo and secondary due to trauma or previous surgery [4].

The etiology of mucoceles is variable and may be due to allergic rhinitis, polyps, inflammation, infection such as chronic sinusitis, trauma, tumors, cystic fibrosis, and previous surgery [10, 15, 16]. They can occur at any age. However, the most frequent age of onset varies between 30 and 60 years, and there is no gender predilection [3, 12]. In pediatric patients, it is rare and may affect the nasolacrimal duct, and if present, it may be associated with cystic fibrosis [10, 17].

The most common location of mucocele is the frontal sinus (60–89 %), followed by the ethmoid sinus (8–30 %), both of which constitute 90 % of cases, possibly because they have a long and convoluted drainage pathway [5], and less frequently the maxillary sinus (10 %) and rarely the sphenoid sinus [10].

The clinical presentation is variable and depends on the location of the mucocele and its extension to other areas. Those located at the frontal level cause frontal

headache, pain, increased volume at the front-orbital level, nasal congestion, and facial asymmetry; when the orbital cavity is invaded, they may present diplopia (45 %), proptosis (83 %), and displacement of the eyeball with alteration of eye movements [11]. Patients presenting posterior ethmoidal and sphenoid mucoceles near cranial nerves II, IV, V, and VI are more frequently associated with visual disturbances and orbital apex syndrome [18]. Extreme care must be taken when the posterior wall of the frontal sinus, which has a thin bone wall, is eroded due to the risk of brain abscess formation, meningitis, or cerebrospinal fluid (CSF) fistula [12].

Computed tomography is the imaging study of choice and helps identify bone lesions associated with mucocele [11, 19]. A homogeneous isodense mass with defined margins and surrounding irregular osteolysis can be seen. Magnetic resonance imaging distinguishes between a mucocele and some aggressive lesions such as encephaloceles, epidermoid cysts, and other tumors [10, 11, 19]. They appear hyperintense on T1-weighted images and isohyperintense on T2-weighted images. Mucoceles present a fine peripheral linear enhancement with a low signal intensity on T1, unlike nasosinusal tumors that present a diffuse enhancement [8].

Surgical management should be focused on optimizing a definitive resolution of symptoms, maintaining an anatomy with normal drainage of the paranasal sinuses, and preventing the risk of recurrence [11]. This implies careful resection of the mucocele and cranialization of the sinuses with obliteration and the placement of adipose tissue grafts, fibrin glue, and bone reconstruction with titanium mesh

Table 1. Clinical features and surgical management of mucocele case reports

Таблица 1. Клинические особенности и хирургическое лечение в клинических описаниях мукоцеле

Author, year Автор, год	Journal Журнал	Country Страна	Cases Случаи	Gender Пол	Age Возраст	Presentation Описание	Surgical intervention Хирургическое вмешательство	Histopathological diagnosis Гистопатологический диагноз	Outcome Исход	Recurrence Рецидив
Moniakis et al., 2024 [20]	Cureus	Greece	1	Male	68	3-cm frontal swelling with no infection; history of head trauma 20 years prior; progressive growth over six months	Bifrontal incision, pericranium preservation, sinus mucosa removal, sinus obliteration with fat graft, fascia lata, and titanium mesh reconstruction	Frontal mucocele	Neurologically intact postoperatively; discharged on day 2; excellent cosmetic result at one-year follow-up	No recurrence reported
Ali., 2024 [12]	International Medical Case Reports Journal	Ethiopia	1	Male	30	4 × 5 cm frontal, firm, non-tender swelling; one-year history post-stick injury; associated headache for one year	Bicoronal incision, bifrontal craniotomy, mucocele excision, sinus mucosa excision, frontal sinus cranialization, pericranial flap application	Frontal mucocele	Completely resolved headache and swelling at one-month follow-up	No recurrence reported
Motazedian et al., 2023 [26]	World Journal of Plastic Surgery	Iran	1	Male	32	Severe headache, large swelling in frontal region, history of forehead trauma and bone cement reconstruction 10 years earlier, smoking, and opium addiction	Excision of mucocele (7 × 8 × 8 cm) and bone cement, drainage of 150 cc of pus, nasal cavity opening, defect covered with titanium mesh, and pedicled galea flap	Not reported	Normal recovery; good cosmetic result; normal at 6-month follow-up	No recurrence reported
Alouda et al., 2023 [15]	International Journal of Surgery Case Reports	Saudi Arabia	1	Male	15	4 cm non-tender fluctuating mass in the right supraorbital region, mild vision decrease, intermittent headaches	Combined surgical approach: endoscopic transseptal to the frontal sinus, sub-brow incision, marsupialization, drain placement	Isolated extra-sinus subcutaneous mucocele	Resolution of mucocele, improved visual acuity, normal eye position, healed sub-brow wound	No recurrence reported
Clarke et al., 2022 [27]	Clinical Case Reports	UK	1	Female	47	Right eye vision loss, proptosis, hypoglobus, exposure keratopathy, ophthalmoplegia, swollen hemorrhagic optic disc	Combined anterior orbitotomy via upper lid skin crease and Functional Endoscopic Sinus Surgery	Frontal sinus mucocele	Resolution of proptosis, restoration of extraocular motility, healed cornea; vision in the right eye not restored	No recurrence reported
Kajal & Verma, 2022 [28]	National Journal of Maxillofacial Surgery	India	1	Male	52	Swelling above the right eye, right eye proptosis, decreased vision, history of road traffic accident 30 years prior, recurrent frontal mucocele with orbital and intracranial extension	Emergency excision of mucocele, recreation of FSOT with silastic stenting, and removal of mucocele contents	Hyalinized collagen tissue with stratified squamous epithelium; mucocele contents	Vision normalized in 1 week, swelling and proptosis resolved within 6 months, FSOT patent at 1-year follow-up	No recurrence reported
Xia., 2021 [29]	Radiology Case Reports	China	1	Male	52	Ocular redness, epiphora, progressive periorbital pain, optic disc edema, intraorbital extension, limitation of adduction in the right eye, mild exotropia	Endoscopic sinus surgery with fronto-ethmoidectomy, mucocele excision, and drainage	Fronto-ethmoidal mucocele with orbital extension	Postoperative resolution of symptoms, full ocular motility, and alignment	Not reported

End of table 1
Окончание табл. 1

Author, year Автор, год	Journal Журнал	Country Страна	Cases Случаи	Gender Пол	Age Возраст	Presentation Описание	Surgical intervention Хирургическое вмешательство	Histopathological diagnosis Диагноз	Outcome Исход	Recurrence Рецидив
Bouhafis et al., 2021 [19]	Annals of Medicine and Surgery	Morocco	1	Male	35	Frontal headache, left proptosis, left upper-medial eyelid swelling, stage 2 nasosinus polyposis, bilateral frontal mucoceles with intraorbital and intracranial extension	Bilateral surgery; Draf IIa procedure, total ethmoidectomy, and Jacques eyebrow approach for excision	Bilateral frontal mucoceles with intraorbital and intracranial extension	Resolution of symptoms; regression of headaches, resolution of exophthalmos, and good postoperative wound healing	Not reported
Maldjian, 2020 [16]	Radiology Case Reports	USA	1	Female	50	Proptosis, restricted eye movements, intermittent eye pain, nasal obstruction, frontal headache, nasal septal perforation, past cocaine abuse	Right orbitotomy, resection of frontoethmoidal mucocele via bicoronal flap approach, ethmoidectomy, frontal sinusotomy, endoscopic maxillary antrostomy	Mucosal tissue with chronic infection and a focal histiocytic aggregate consistent with mucocele	Improvement in symptoms; no recurrence reported at the time of follow-up	No recurrence reported
Alhassan et al., 2020 [11]	International Journal of Surgery Case Reports	Saudi Arabia	1	Male	17	Chronic sinusitis with bilateral nasal obstruction, anosmia, left frontal headache, displaced left eye, and recurrent epistaxis	Endonasal endoscopic image-guided surgery (Draf type 2b)	Not reported	Complete resolution and normal aeration of the sinuses (6 months post-op)	No recurrence reported
Bosmans & Vanhoenacker, 2020 [10]	Journal of the Belgian Society of Radiology	Belgium	1	Female	72	Left forehead bump after a fall, progressive memory loss, recurrent falls, and progressive expansion of the frontal bone	Neurosurgical resection	Not reported	Complete resolution after resection	No recurrence reported

Note. FSOT – Frontal sinus outflow tract.
Примечание. FSOT – выводящий тракт лобной пазухи.

[20]. To choose the appropriate surgical approach, the patency of the frontal sinus drainage and the feasibility of endoscopic access must be considered. If this is not possible, a modified Lothrop endoscopic approach (MELP) can be used, which allows greater access to the frontal sinuses and lateral regions or surgery with an osteoplastic flap. However, MELP has a higher risk of CSF fistula and requires more excellent training by the surgeon [11].

In addition, there is a classification [21] for the choice of surgical approach in the case of frontal sinus mucoceles, depending on the erosion of the sinus wall with or without intraorbital or intracranial extension. Type 1: Located only in the frontal sinus (with or without orbital extension); Type 2: Located in the frontoethmoidal sinus (with or without orbital extension); Type 3: Erosion of the posterior wall of the sinus; Type 3A: with minimal or no intracranial extension; Type 3B: with significant intracranial extension; Type 4: erosion of the anterior wall; Type 5: erosion of both anterior and posterior walls; Type 5A: minimal or no intracranial extension.

Frontal mucoceles can be treated by endonasal, external, or combined endoscopic approaches [19], but this will depend on the size, extent, and degree of accessibility [15]. The open approach allows direct access to the frontal and ethmoid sinus, adequate exposure, and mucocele removal to perform complete obliteration and prevent recurrence [22]. Endoscopic approaches can be complex if the mucocele expands to the intracranial region [23]. Endoscopic surgery with marsupialization has been gaining ground and is currently considered the technique of choice [9, 19], since it allows a functional aerated sinus. However, it is not free of complications such as direct trauma to the orbital content, optic nerve injury, intraorbital hemorrhage, abscesses, or recurrence of the mucocele.

In case of injury to the posterior wall of the frontal sinus, infections such as meningitis, epidural abscess, subdural empyema, and brain abscesses may occur [11]. In addition, due to endoscopic marsupialization, the circumferential area tends to become stenosed, and the mucocele tends to recur [24].

Among the most frequent complications, recurrence, infections such as meningitis, epidural abscess, subdural abscess, and brain abscess have been reported. For this reason, lifelong monitoring is recommended since recurrence can occur even years after surgical management in 3 to 35 % of cases [15, 19]. The endoscopic approach can be complicated by CSF fistula, amaurosis, blood loss, and potentially fatal infections. Open approaches may have more complications but are minor, such as epistaxis, temporary vision changes, abnormal scarring, injury to sensory nerves, and non-fatal infections [25].

In our case, cranial surgery was chosen due to familiarity with the surgical technique and the team of neurosurgeons and anesthesiologists. In addition, it was evident that the frontal sinus's posterior wall was eroded, indicating open surgery. This allowed us to have direct access and perform a correct removal of the mucocele with cranialization of the sinus and complete obliteration of the same, which with an endoscopic approach would have been more complicated.

CONCLUSION

Mucoceles are benign pathologies, but due to their potentially invasive behavior, they must be treated immediately through a surgical approach that achieves total resection, cranialization, and prevention of recurrence and infections. In our setting, the open approach offers adequate exposure, complete removal, and a lower risk of recurrence.

References | Литература

- Lund V.J., Milroy C.M. Fronto-ethmoidal mucocoeles: a histopathological analysis. *J Laryngol Otol* 1991;105(11):921–3.
- Borkar S., Tripathi A.K., Satyarthee G. et al. Frontal mucocele presenting with forehead subcutaneous mass: an unusual presentation. *Turk Neurosurg* 2008;18(2):200–3.
- Santos P.L.D., Chihara L.L., Alcalde L.F.A. et al. Outcomes in Surgical Treatment of Mucocele in Frontal Sinus. *J Craniofac Surg* 2017;28(7):1702–8.
- Scangas G.A., Gudis D.A., Kennedy D.W. The natural history and clinical characteristics of paranasal sinus mucoceles: a clinical review. *Int Forum Allergy Rhinol* 2013;3(9):712–7.
- Chowdhury R., Aldajani A., Almhanedi H. et al. Paranasal Sinus Mucoceles With Intraorbital and Intracranial Involvement: A Case Series Analysis and Surgical Outcomes Assessment. *Annals of Otolaryngology and Laryngology* 2024;134(3):225–33. DOI: 10.1177/00034894241300806
- Rutledge W.C., Ozair A., Villanueva-Meyer J.E. et al. “Open-window” craniectomy for the removal of frontal sinus mucosa to prevent a delayed mucocele: illustrative case. *J Neurosurg Case Lessons* 2024;7(9):CASE23654. DOI: 10.3171/CASE23654
- Weidmayer S. Frontal mucocele with intracranial extension causing frontal lobe syndrome. *Optom Vis Sci* 2015;92(6):e138–42.
- Peral Cagigal B., Barrientos Lezcano J., Floriano Blanco R. et al. Frontal sinus mucocele with intracranial and intraorbital extension. *Med Oral Patol Oral Cir Bucal* 2006;11(6):E527–30.
- Stokken J., Wali E., Woodard T. et al. Considerations in the management of giant frontal mucoceles with significant intracranial extension: A systematic review. *Am J Rhinol Allergy* 2016;30(4):301–5. DOI: 10.2500/ajra.2016.30.4323
- Bosmans F., Vanhoenacker F. Giant Frontal Paranasal Mucocele: Case Report and Review of the Literature. *J Belg Soc Radiol* 2020;104(1):48. DOI: 10.5334/jbsr.2117
- Alhassan Z., Molani F., Almomen A. Endoscopic management of bilateral frontal mucopyoceles: A Case Report and Literature review. *Int J Surg Case Rep* 2020;68:208–13. DOI: 10.1016/j.ijscr.2020.02.039
- Ali E.H. Post Traumatic Frontal Sinus Mucocele with Subcutaneous Extension: A Case Report and Literature Review. *Int Med Case Rep J* 2023;16:599–604. DOI: 10.2147/IMCRJ.S436224

13. Kass E.S., Fabian R.L., Montgomery W.W. Manometric study of paranasal sinus mucoceles. *Ann Otol Rhinol Laryngol* 1999;108(1):63–6. DOI: 10.1177/000348949910800109
14. Mineck C.W., Chandra R.K., Cohen N. Orbital mucopyocele after the use of alloplastic materials in the management of frontal sinus fractures. *Otolaryngol Head Neck Surg* 2006;135(6):974–6. DOI: 10.1016/j.otohns.2005.09.011
15. Alouda N., Alkhiary H., Alsaleh S. Isolated extra-sinus subcutaneous mucocele: A case report. *Int J Surg Case Rep* 2023;109:108488. DOI: 10.1016/j.ijscr.2023.108488
16. Maldjian C. Giant mucocele secondary to cocaine abuse. *Radiol Case Rep* 2020;16(3):589–92. DOI: 10.1016/j.radcr.2020.12.025
17. Nicollas R., Facon F., Sudre-Levillain I. et al. Pediatric paranasal sinus mucoceles: etiologic factors, management and outcome. *Int J Pediatr Otorhinolaryngol* 2006;70(5):905–8. DOI: 10.1016/j.ijporl.2005.10.002
18. Li E., Howard M.A., Vining E.M. et al. Visual prognosis in compressive optic neuropathy secondary to sphenoid sinus mucocele: A systematic review. *Orbit* 2018;37(4):280–6. DOI: 10.1080/01676830.2017.1423087
19. Bouhafis K., Lachkar A., Bouamama T. et al. Bilateral orbito-cerebral-extending frontal mucocele following nasosinus polyposis: A case report. *Ann Med Surg (Lond)* 2021;66:102432. DOI: 10.1016/j.amsu.2021.102432
20. Moniakis A., Malli A., Smponias V., Kasapas K. Delayed Post-traumatic Frontal Mucocele Occurrence: A Case Report. *Cureus* 2024;16(8):e67108. DOI: 10.7759/cureus.67108
21. Har-El G. Transnasal endoscopic management of frontal mucoceles. *Otolaryngol Clin North Am* 2001;34(1):243–51. DOI: 10.1016/s0030-6665(05)70309-1
22. Haug G.A., Dortzbach R.K., Brandenburg J. Treatment of frontal sinus mucoceles with the osteoplastic flap technique. *Ophthalmic Surg* 1978;9(4):40–66.
23. Pia F., Aluffi P., Borello G. Frontal mucocele: open surgery. *Acta Otorhinolaryngol Ital* 1999;19(3):155–9. (In Italian).
24. Khong J.J., Malhotra R., Selva D., Wormald P.J. Efficacy of endoscopic sinus surgery for paranasal sinus mucocele including modified endoscopic Lothrop procedure for frontal sinus mucocele. *J Laryngol Otol* 2004;118(5):352–6. DOI: 10.1258/002221504323086534
25. Courson A.M., Stankiewicz J.A., Lal D. Contemporary management of frontal sinus mucoceles: a meta-analysis. *Laryngoscope* 2014;124(2):378–86. DOI: 10.1002/lary.24309
26. Motazedian G., Koushki E., Nahaei M. et al. A Giant Frontal Sinus Mucocele in an Opium Addict Patient: A Case Report. *World J Plast Surg* 2023;12(2):107–11. DOI: 10.52547/wjps.12.2.107
27. Clarke K.M., Wilde C., Walker A. et al. Frontal sinus mucocele with orbital extension drained via a combined upper lid skin crease and endoscopic approach. *Clin Case Rep* 2022;10(8):e6206. DOI: 10.1002/ccr3.6206
28. Kajaal S., Verma H. Frontal sinus stenting: A feasible option for post-traumatic recurrent giant mucocele compromising vision. *Natl J Maxillofac Surg* 2022;13(3):484–7. DOI: 10.4103/njms.njms_476_21
29. Xia Y. A Fronto-ethmoidal Sinus Mucocele presenting with optic disc edema. *Radiol Case Rep* 2021;16(11):3410–3. DOI: 10.1016/j.radcr.2021.07.091

ORCID of author / ORCID автора

Gino Vasquez Paredes: <https://orcid.org/0000-0001-6192-2218>

Conflict of interest. The author declares no conflict of interest.

Конфликт интересов. Автор заявляет об отсутствии конфликта интересов.

Funding. The work was performed without external funding.

Финансирование. Работа выполнена без спонсорской поддержки.

Compliance with patient rights. The patient gave written informed consent to the publication of her data.

Соблюдение прав пациентов. Пациентка подписала информированное согласие на публикацию своих данных.

Article submitted: 28.01.2025. **Accepted for publication:** 11.12.2025. **Published online:** 10.04.2026.

Статья поступила: 28.01.2025. **Принята к публикации:** 11.12.2025. **Опубликована онлайн:** 10.04.2026.