

The sequential rupture of two cerebral aneurysms

Contacts:

Anna Olegovna Gavrilova
anna-gavrilova20@yandex.ru

P.G. Shnyakin^{1,2}, A.O. Gavrilova¹

¹Prof. V.F. Voino-Yasenetsky Krasnoyarsk State Medical University; 1 Partizana Zheleznyaka St., Krasnoyarsk 660022, Russia;

²Regional Clinical Hospital; 3 Partizana Zheleznyaka St., Krasnoyarsk 660022, Russia

The treatment of patients with multiple cerebral aneurysms in the acute period of subarachnoid hemorrhage may be associated with strategy difficulties, since it is not always obvious which of the aneurysms is responsible for intracranial hemorrhage. This aspect is of paramount importance, since it is the ruptured aneurysm should be first treated. The combination treatment of all multiple aneurysms during one surgical intervention using all possible facilities (microsurgery, endovascular surgery or hybrid technologies) is the ideal. However, in the acute period of hemorrhage, this is not always possible. Currently, the criteria for revealing the ruptured aneurysms among the multiple ones are well known and they are helpful in the most cases.

However the sequential rupture of two aneurysms is described in few papers, and it must be taken into account, even with a low probability. There are no more than a dozen such cases described in the literature.

This article demonstrates a clinical case of a 58 year old woman with subarachnoid-parenchymal hemorrhage, in whom, according to brain computed tomography and intraoperative situation, it is highly likely that two cerebral aneurysms rupture can be assumed.

Keywords: multiple cerebral aneurysms, subarachnoid hemorrhage, combined rupture, sequential rupture

For citation: Shnyakin P.G., Gavrilova A.O. The sequential rupture of two cerebral aneurysms. *Neyrokhirurgiya = Russian Journal of Neurosurgery* 2025;27(4):80–5.

DOI: <https://doi.org/10.63769/1683-3295-2025-27-4-80-85>

BACKGROUND

Cerebral aneurysms occur in 2–6 % of the population. Two or more aneurysms are observed in 20–25 % of all aneurysmal cases. Subarachnoid hemorrhage (SAH) occur with a frequency of 9–12 cases per 100,000 population per year [1–4].

In the acute phase of SAH in patients with multiple aneurysms, it is not always easy to determine which aneurysm is the cause of the hemorrhage. However, the answer to this question is crucial for surgical planning.

In the acute period of hemorrhage in case of multiple aneurysms, the excluding all of them from the bloodstream during a single surgical intervention solves a number of problems: 1) guaranteed exclusion of the ruptured aneurysm; 2) safe correction of arterial hypertension in the postoperative period; 3) eliminating the requirement for repeated intervention.

For multiple aneurysms, endovascular techniques may have advantages over microsurgery, including the ability to operate aneurysms in different circulations and from both sides. However, there are limitations to the use of these techniques in the acute period of hemorrhage, including the necessity for stent placement, which requires dual antiplatelet therapy.

During the microsurgical interventions, the primary goal is to identify and operate the ruptured aneurysm and, if possible, all others, if this is not accompanied by a significant increase in intervention trauma.

The following criteria are the most often used to select the most likely ruptured aneurysm:

- the largest size;
- the irregular shape, irregular contour;
- the diverticules;
- the maximal hemorrhage (blood clot) in the projection of the aneurysm;
- the spasm of the parent artery [1, 5].

Although these criteria are not absolute in identifying a ruptured aneurysm, they are helpful in making the correct decision in most cases. However, a study by C.L. Sturiale et al. (2024), which included 62 patients with 161 aneurysms, showed that the ruptured aneurysm could not be identified in 9.7 % of cases [6]. Therefore, if there is any doubt about the ruptured aneurysm, it is necessary to try operating all aneurysms.

However, even with certainty in identifying the ruptured aneurysm, the possibility that two aneurysms may have ruptured simultaneously cannot be completely ruled out. This is very rare, but it should not be ignored.

We present our clinical case of an elderly female patient with subarachnoid-parenchymal hemorrhage due to the combined sequential rupture of the internal carotid artery (ICA) bifurcation aneurysm and anterior communicating artery (ACoA) aneurysm.

CLINICAL CASE

Female patient N., 58 years old, was admitted by ambulance to the regional vascular center complaining of a severe headache.

While examining in the emergency room, she was conscious (15 points on the Glasgow Coma Scale), her cranial nerves were intact, there was no limb paresis or other focal symptoms, nuchal rigidity was 5 cm, and Kernig's sign was 100°.

The brain multispiral computed tomography (MSCT) was performed, revealing a subarachnoid-parenchymal hemorrhage in the basal cisterns (Fig. 1). MSCT angiography revealed a 2.8 mm miliary aneurysm of the right ICA bifurcation and a 5.6 mm aneurysm of the right ACoA (Fig. 2).

Based on native imaging and angiogram data, the ICA bifurcation aneurysm was located in the center of the blood

clot, in the right carotid cistern, while the ACoA aneurysm was located within the blood clot in the interhemispheric fissure. As can be seen in Figure 1, both clots are quite clearly isolated from each other. Furthermore, there is minimal blood in the ambient cistern, which may also indicate the separate nature of the hemorrhages.

The rupture of the right ICA aneurysm (combined with ACoA aneurysm rupture) was suggested not only by the large blood clot in its projection, but also by the large amount of blood in the right Sylvian fissure and the almost complete absence of blood in the left Sylvian fissure (see Fig. 1).

Thus, based on the data from the native images and the CT angiography, the sequential rupture of both aneurysms was suspected. The diagnosis was the following: subarachnoid-parenchymal hemorrhage due to rupture of the right ICA bifurcation aneurysm and the rupture of ACoA aneurysm; Hunt – Hess score: grade II, Fisher score: grade IV.

Given the very acute stage of the hemorrhage and the patient's compensated condition, the decision was made to perform surgical treatment. The right lateral supraorbital approach was performed with the following microsurgical clipping of both right ICA bifurcation and ACoA aneurysms.

Intraoperatively, an aneurysm with a narrow neck and thin purple wall was identified in the area of the right ICA bifurcation (Fig. 3). The aneurysm was clipped. The A1 segment of the right anterior cerebral artery was then dissected, and the ACoA was accessed along it. An aneurysm with a superiorly and posteriorly directed base was detected in the ACoA area (see Fig. 3). During an attempt to apply a permanent clip, the aneurysm has been ruptured. After temporary clipping of both anterior cerebral arteries (for 4 minutes), the clip was replaced with total closure of the aneurysm.

The postoperative period was complicated by the development of severe decompensated vasospasm with increased linear blood flow velocity in both middle cerebral arteries (>300 cm/s) and the development of secondary ischemic areas. The patient was discharged on the 18th postoperative day with a Rankin Scale score of 4.

DISCUSSION

Although the term “simultaneous” (synchronous) is used in foreign publications to describe the rupture of two aneurysms, it cannot be considered entirely correct. It is unlikely that two aneurysms rupture simultaneously. Rather, one can assume a sequential rupture of two aneurysms over a short period of time. Thus, K. Hou et al. (2016), who described a case of rupture of two aneurysms in a 68-year-old patient, use the more accurate term “early sequential rupture”. In their case, the rupture of two aneurysms occurred within 1 day [7].

Early sequential ruptures of two aneurysms, although unlikely, are nonetheless possible. For example, there are observations of hypertensive intracerebral hemorrhages of multiple locations simultaneously [8, 9]. If normal arteries (altered by hypertension) can undergo sequential

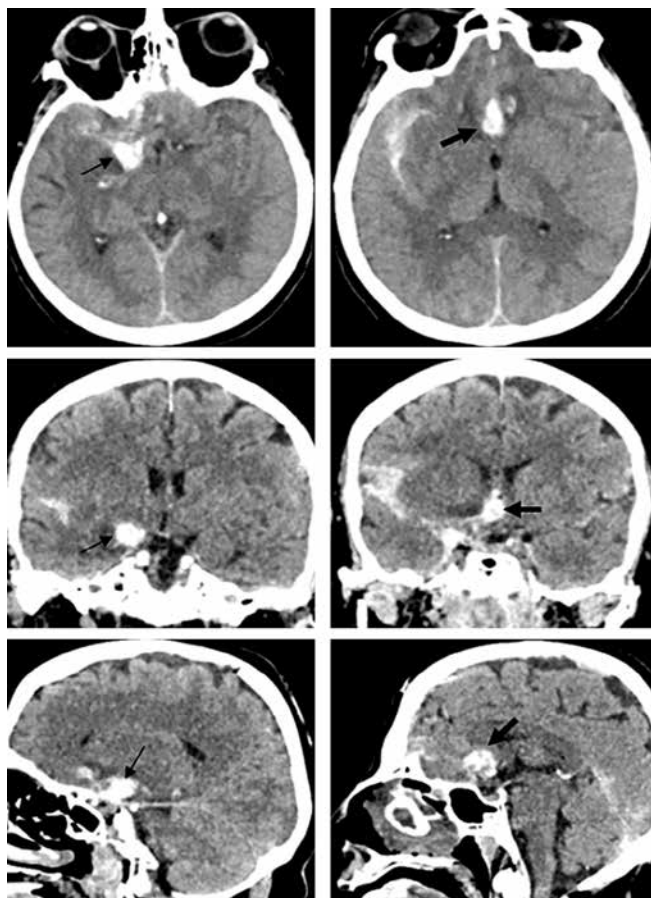


Fig. 1. Brain multispiral computed tomography of female patient N. (native). A thin black arrow shows a hemorrhage in the area of the bifurcation of internal carotid artery aneurysm, a thick black arrow shows a hemorrhage in the area of the anterior communicating artery aneurysm

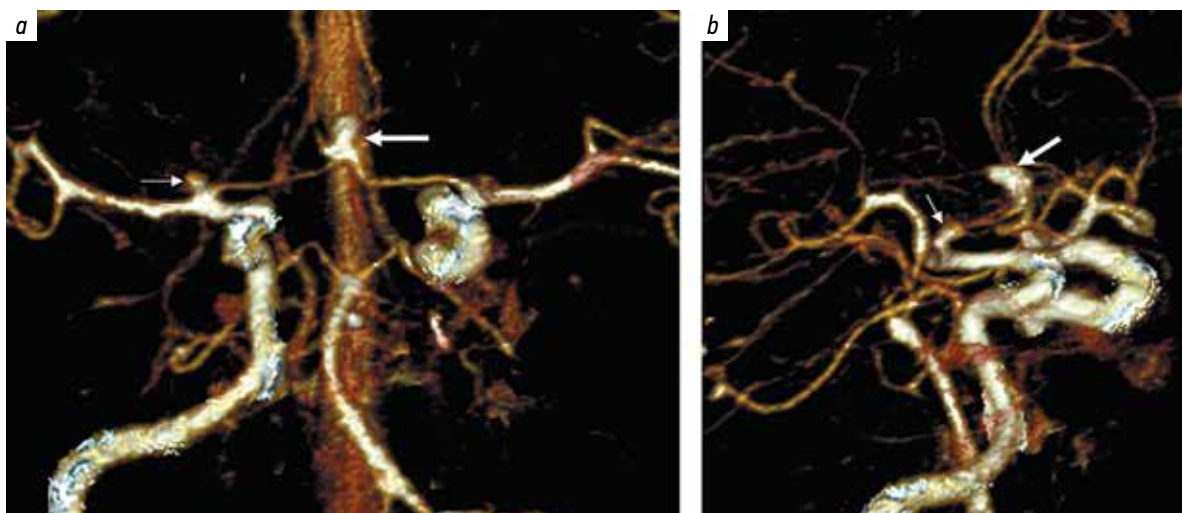


Fig. 2. Multispiral computed tomography angiography of patient N. in direct (a) and lateral (b) projections (3D reconstruction). A thin white arrow indicates an aneurysm of the right internal carotid artery bifurcation, a thick white arrow indicates an aneurysm of the anterior communicating artery

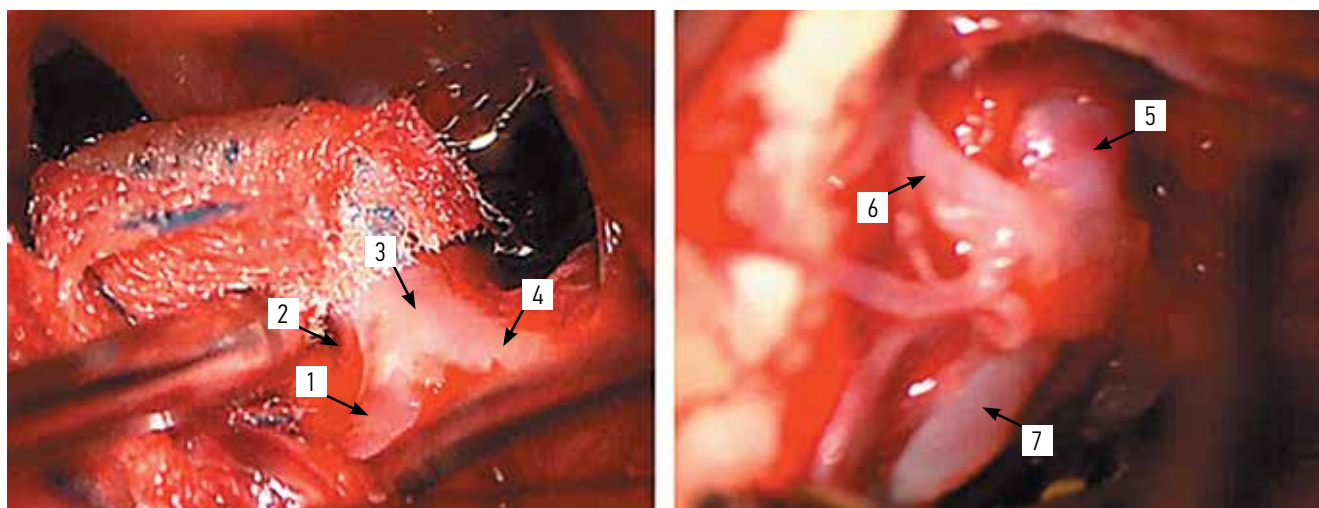


Fig. 3. Intraoperative images of patient N. (Kinevo 900 operating microscope). 1 – aneurysm of the bifurcation of the right internal carotid artery; 2 – A1-segment of the right anterior cerebral artery; 3 – bifurcation of the right internal carotid artery; 4 – right middle cerebral artery; 5 – aneurysm of the anterior communicating artery; 6 – A2-segment of the right anterior cerebral artery; 7 – A2-segment of the right anterior cerebral artery

ruptures over a short period of time, this is even more likely with cerebral aneurysms.

It is likely that the following pathogenetic mechanism of sequential ruptures of cerebral aneurysms occurs: rupture of the 1st aneurysm leads to SAH (which is accompanied by an increase in intracranial pressure), the initiation of the Cushing reflex and an even greater increase in systemic arterial pressure, which leads to the rupture of the 2nd aneurysm.

J. Yoon et al. (2023) report a case of a 21-year-old female patient with a ruptured aneurysm of the right posterior communicating artery, which underwent microsurgical clipping in the acute period of hemorrhage. After the surgery, the patient was treated in the hospital, and on the 16th day, an aneurysm of the left anterior choroid artery ruptured, having almost doubled in size during this time

[10]. In a study by T. Anda et al. (2006), it was proven that in the acute period of aneurysmal SAH, an increase in systolic blood pressure to 200 mm Hg and the development of vasospasm are significant factors for the rapid enlargement of concomitant aneurysms, and therefore for increase of their rupture risk [11].

Accordingly, in the acute period of SAH in case of multiple aneurysms, it is necessary not only to identify a single ruptured aneurysm but also to consider the possibility for rupture of two aneurysms sequentially. In our clinical case, the rupture of ACoA aneurysm was initially considered due to its larger size comparing to ICA aneurysm. However, the character of the hemorrhage, as well as the intraoperative findings, strongly suggest the sequential rupture of both aneurysms.

There are few publications in the literature devoted to the combined rupture of two aneurysms.

The first description of a combined rupture of two cerebral aneurysms was found in the article by J.N. Joslyn et al. “Simultaneous rupture of two intracranial aneurysms: CT diagnosis”, published in 1985. This paper presents a case of SAH in a 37-year-old female patient with multiple aneurysms. Taking into account the localization of hemorrhages (according to MSCT data), the authors concluded that there was a simultaneous rupture of a pericallosal artery aneurysm and a middle cerebral artery aneurysm [12].

H. Tsurushima et al. (1996) described the clinical case of a 68-year-old man admitted with complaints of severe headache. MSCT revealed SAH in the interhemispheric fissure and an intracerebral hematoma in the projection of the right Sylvian fissure. Angiography revealed aneurysms of the ACoA and right middle cerebral artery. Taking into account the different localization of hemorrhages, the authors concluded that rupture of two aneurysms was probable [13].

S. Havakeshian et al. (2013) reported a case of combined hemorrhage from two aneurysms located in the middle cerebral artery – M1 segment and MCA bifurcation. The authors hypothesized the simultaneous rupture of these two aneurysms, taking into account the separate hemorrhages

(intracerebral hematomas) based on MSCT and intraoperative findings [14].

J.L. Dubois et al. (2016) described a case of combined rupture of two aneurysms (the posterior communicating artery and the middle cerebral artery) in an article with the clickbait title “Subarachnoid hemorrhage from the rupture of two intracranial aneurysms on the same day: a rare occurrence, not a myth” [15].

It’s worth noting that in our clinical case, as in all the clinical cases described in the mentioned above studies, we can only consider the high probability of combined rupture of two aneurysms, but this is virtually impossible to prove. However, it’s better to be mistaken in concluding that two aneurysms are likely to rupture than to consider one of the ruptured aneurysms as asymptomatic and not exclude it from the bloodstream.

CONCLUSION

The assumption that only one aneurysm ruptures in the case of multiple ones may be misleading. This clinical case confirms the necessity to evaluate the criteria for the most likely rupture of one of the multiple aneurysms, but not to focus solely on finding a single ruptured aneurysm and to allow for the possibility of two aneurysms rupturing sequentially.

References

1. Surgery of brain aneurysms. Ed. by V.V. Krylov. In 3 volumes. Moscow: T.A. Alekseeva, 2011. (In Russ.).
2. Eliava Sh.Sh., Konovalov A.N., Grebenev F.V. et al. Screening of patients with cerebral aneurysms: mathematical analysis and economic justification. *Zhurnal Voprosy neyrokhirurgii im. Burdenko = Burdenko’s Journal of Neurosurgery* 2023;87(1):15–24. (In Russ., In Engl.). DOI: 10.17116/neiro20238701115
3. Vlak M.H., Algra A., Brandenburg R., Rinkel G.J. Prevalence of unruptured intracranial aneurysms, with emphasis on sex, age, comorbidity, country, and time period: a systematic review and meta-analysis. *Lancet Neurol* 2011;10(7):626–36. DOI: 10.1016/S14744422(11)70109-0
4. Murayama Y., Takao H., Ishibashi T. et al. Risk analysis of unruptured intracranial aneurysms: prospective 10-year cohort study. *Stroke* 2016;47(2):365–71. DOI: 10.1161/STROKEAHA.115.010698
5. Karttunen A.I., Jartti P.H., Ukkola V.A. et al. Value of the quantity and distribution of subarachnoid haemorrhage on CT in the localization of a ruptured cerebral aneurysm. *Acta Neurochir (Wien)* 2003;145(8):655–61; discussion 661. DOI: 10.1007/s00701-003-0080-8
6. Sturiale C.L., Auricchio A.M., Skrap B. et al. The clinical challenge of subarachnoid hemorrhage associated with multiple aneurysms when the bleeding source is not certainly identifiable. *J Neurosurg Sci* 2024;68(3):301–9. DOI: 10.23736/S0390-5616.21.05609-5
7. Hou K., Zhao J., Zhang Y. et al. Simultaneous or early sequential rupture of multiple intracranial aneurysms: a rare and insufficiently understood entity. *World Neurosurg* 2016;89:727.e1–4. DOI: 10.1016/j.wneu.2016.01.007
8. Shiomi N., Miyagi T., Koga S. et al. [Simultaneous multiple hypertensive intracerebral hematoma (In Japanese)]. *No Shinkei Geka* 2004;32(3):237–44.
9. Laiwattana D., Sangsawang B., Sangsawang N. Primary multiple simultaneous intracerebral hemorrhages between 1950 and 2013: analysis of data on age, sex and outcome. *Cerebrovasc Dis Extra* 2014;4(2):102–14. DOI: 10.1159/000362111
10. Yoon J., Goh R., Winter C. Sequential rupture of two concomitant cerebral aneurysms. *Br J Neurosurg* 2025;39(3):375–9. DOI: 10.1080/02688697.2023.2233607
11. Anda T., Yonekura M., Baba H. et al. Factors affecting rapid growth of unruptured cerebral aneurysms during the acute stage of subarachnoid hemorrhage. *Neurol Res* 2006;28(2):165–71. DOI: 10.1179/016164105X48806
12. Joslyn J.N., Williams J.P., White J.L. Simultaneous rupture of two intracranial aneurysms: CT diagnosis. *Stroke* 1985;16(3):518–21. DOI: 10.1161/01.str.16.3.518
13. Tsurushima H., Meguro K., Narushima K. et al. [Simultaneous rupture of multiple intracranial aneurysms: a case report (In Japanese)]. *No Shinkei Geka* 1996;24(4):385–8.
14. Havakeshian S., Bozinov O., Burkhardt J.-K. et al. Simultaneous rupture of two middle cerebral artery aneurysms presented with two aneurysm-associated intracerebral hemorrhages. *J Neurol Surg A Cent Eur Neurosurg* 2013;74(Suppl 1):e233–6. DOI: 10.1055/s-0033-1345101
15. Dubois J.L., Major O. Subarachnoid haemorrhage from the rupture of two intracranial aneurysms in the same day: a rare occurrence, not a myth. *BMJ Case Rep* 2016;2016:bcr2015213027. DOI: 10.1136/bcr-2015-213027

Authors' contributions

P.G. Shnyakin: collecting data for analysis, analysis of the data obtained, patient monitoring, article writing;
A.O. Gavrilova: analysis of publications on the topic of the article, article writing.

ORCID of authors

P.G. Shnyakin: <https://orcid.org/0000-0001-6321-4557>

A.O. Gavrilova: <https://orcid.org/0009-0000-4511-5774>

Conflict of interest. The authors declare no conflict of interest.

Funding. The work was performed without external funding.

Compliance with patient rights. The patient gave written informed consent to the publication of her data.