

# The surgical treatment of tentorial and transverse sinus meningiomas

## Contacts:

Dmitry Aleksandrovich  
Kulichkov  
[neurosurgeryda@gmail.com](mailto:neurosurgeryda@gmail.com)

D.A. Kulichkov<sup>1</sup>, G.Y. Grigoryan<sup>1</sup>, O.N. Dreval<sup>2</sup>, Y.A. Grigoryan<sup>1</sup>

<sup>1</sup>Treatment and Rehabilitation Center, Ministry of Health of Russia; 3 Ivankovskoye Shosse, Moscow 125367, Russia;

<sup>2</sup>Russian Medical Academy of Continuous Professional Education, Ministry of Health of Russia; Bld. 1, 2/1  
Barrikadnaya St., Moscow 125993, Russia

**Background.** The growth zone of tentorial and transverse sinus meningiomas (TTSM) are located on the wall of the transverse sinus and tentorium cerebelli, and tumors often extend into the lumen of the sinus, causing its complete or partial occlusion.

**Aim.** To evaluate the clinical manifestations, relationships with venous sinuses, and results of surgical treatment of TTSM.

**Materials and methods.** The study includes 46 patients with TTSM who underwent surgical treatment (7 men and 39 women aged 37 to 75 years old). In 35 cases a subtentorial approach was performed, and in 11 cases a supratentorial approach was used. In 16 cases, a paramedian suboccipital craniotomy was performed for medial tumor location, and a median suboccipital craniotomy was used in 7 cases. A retrosigmoid craniotomy was done in 13 cases for lateral tumor location, and an occipital craniotomy was performed in 9 patients for isolated supratentorial growth (5 cases) and for sub- and supratentorial growth (4 cases). In 1 case, a posterior temporal craniotomy was used for supra- and subtentorial tumor spread. Tentoriotomy was performed in 15 cases to resect the growth zone on the tentorium cerebelli.

**Results.** The average tumor size was 37.6 (11–79) mm, and occlusive hydrocephalus was detected in 5 patients. In 27 cases, the tumor extended subtentorially, in 7 cases – supratentorially, and in 12 cases – both supra- and subtentorially. The typical neurological manifestation was ataxic syndrome, observed in 36 cases. The cranial nerve involvement was noted in 4 cases, which were represented by impaired function of the V nerve (hypoesthesia) in 1 patient and dysfunction of the VIII nerve in 3 patients. Homonymous hemianopsia was observed in 1 patient, and decreased visual acuity was detected in 7 cases. Total resection, corresponding to the Simpson grade II, was performed in 42 patients, and in 4 cases the tumor was subtotally removed (the Simpson grade III). The onset or increase of ataxic disorders was detected in 6 patients, and 1 patient with pronounced supratentorial growth experienced transient homonymous hemianopsia, which regressed after 2–3 weeks. Two patients developed venous infarction of the cerebellar hemisphere.

**Conclusion.** The goal of surgical interventions for TTSM is maximal resection of tumor tissue while preserving venous outflow through the sinuses and collateral veins, which ensures the preservation of cerebral structures and minimizes the risk of neurological complications.

**Keywords:** meningioma, tentorium cerebelli, transverse sinus

**For citation:** Kulichkov D.A., Grigoryan G.Y., Dreval O.N., Grigoryan Y.A. Surgical treatment of tentorial and transverse sinus meningiomas. *Neurokhirurgiya = Russian Journal of Neurosurgery* 2025;27(4):28–36.

DOI: <https://doi.org/10.63769/1683-3295-2025-27-4-28-36>

## BACKGROUND

Meningiomas are extracerebral tumors originating from the meningotheial cells of the dura mater and arachnoid, as well as the choroid plexus of the cerebral ventricles, and are significantly more common in women aged 30 to 50 years. Meningiomas account for 24–30 % of all intracranial tumors [1], and in 30 % of cases, the tumor growth zone is located in the tentorium cerebelli, with approximately 25 % of them extending into the transverse sinus region.

The enlargement of tentorium cerebelli and transverse sinus meningiomas (TTSM) is accompanied by compression

of the cerebellum, occipital and temporal lobes, arteries and veins, and obstruction of cerebrospinal fluid outflow. TTSM growth zones are located on the wall of the transverse sinus and tentorium cerebelli, and tumors often extend into the sinus lumen, causing its complete or partial occlusion.

The clinical manifestations, surgical technique, and treatment outcomes vary significantly depending on tumor size, the presence of cerebellar compression, and the extent of tumor invasion into the transverse sinus. The postoperative mortality is no more than 3.7 %, but the incidence

of neurological complications varies from 19 to 55 %, highlighting the necessity for new approaches to the surgical treatment of TTSM [2, 3].

The **aim** of the study was to evaluate clinical manifestations, relationships with venous sinuses and the results of surgical treatment of TTSM.

#### MATERIALS AND METHODS

The study included 46 patients with TTSM treated between 2010 and 2024: 7 men (15.2 %) and 39 women (84.8 %), aged 37 to 75 years (mean age 57.2 years) (Table 1). In 4 cases, patients underwent surgery for continued TTSM growth. Tumors located in the region of the superior jugular bulb were classified as meningiomas of the petrous bone and foramen magnum; such cases were not included in the study.

All patients underwent the neurological examination, magnetic resonance imaging (MRI), and computed tomography (CT) scans with contrast to determine the tumor size and relationship to surrounding brain structures. CT-venography and MRI venography were performed to estimate the patency of the transverse and sigmoid sinuses as well as the extent of tumor invasion, and the dominant side of the sinus.

The tumor spread to the venous sinuses was assessed according to the grading of M. Sindou and P. Hallacq [4], developed for parasagittal meningiomas: type I – the tumor is adjacent to the sinus or its lacunae, but does not invade it; type II – the tumor invades the roof or lateral wall of the sinus; type III – the parasinus and sinus recess are affected; type IV – involvement of the lateral and superior walls of the sinus; type V – all walls are involved, while the tumor is located only on one side, whereas in type VI all walls are involved and the tumor is located on both sides of the sinus (Fig. 1, Table 2).

According to the classification of S.K. Hwang et al. [5], the drainage variants through the transverse sinuses

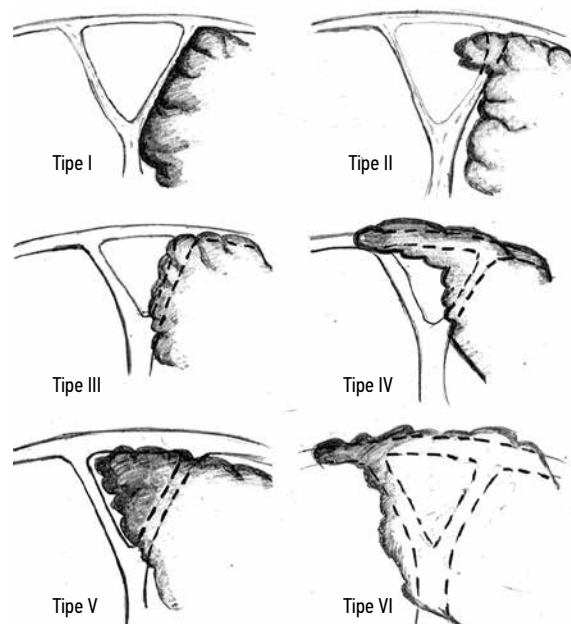


Fig. 1. The relationships of meningiomas with venous sinuses (see description in the text) (according to [4])

in the presented series of observations were divided into type A – transverse sinuses are symmetrical on both sides (26 cases), type B – on the tumor side – non-dominant sinus (10 cases), type C – dominant sinus on the tumor side (8 cases), type D – presence of only 1 sinus with contralateral agenesis (2 cases). The types of tumor invasion of the sinuses in the studied group of patients are presented in Table 2.

The choice of surgical approach was based on the location of the tumor node relative to the tentorium cerebelli and the location of the tumor growth zone. The subtentorial approach was used in 35 cases (76 %), and the supratentorial approach was performed in 11 cases (24 %).

Table 1. Main characteristics of patients with tentorial and transverse sinus meningiomas ( $n = 46$ )

Parameters	Subtentorial meningiomas ( $n = 27$ )	Supratentorial meningiomas ( $n = 7$ )	Sub- and supratentorial meningiomas ( $n = 12$ )
Average age (range), years	57 (41–74)	58 (45–73)	54 (37–75)
Sex, $n$ (%):			
female	24 (88.8)	6 (85.7)	9 (75)
male	3 (11.2)	1 (14.3)	3 (25)
Tumor location side, $n$ (%):			
right	15 (55.5)	3 (42.8)	6 (50)
left	12 (44.5)	4 (57.2)	6 (50)
Average tumor size (range), mm	34 (11–53)	37 (27–68)	46 (30–79)
Compression $n$ (%):			
brain stem	2 (7.4)	0	3 (25)
cerebellum	27 (100)	0	12 (100)
Totally of resection, $n$ (%):			
total	25 (92.6)	6 (85.7)	11 (91.6)
subtotal	2 (7.4)	1 (14.3)	1 (8.4)

Table 2. Types of sinus invasion by tumor

Sinus/distribution	Type of invasions, <i>n</i>					
	I	II	III	IV	V	VI
Transverse sinus:	12	13	3	5	8	5
subtentorial distribution	7	6	1	4	6	3
supratentorial distribution	1	4	1	0	1	0
sub- and supratentorial distribution	4	3	1	1	1	2
Sigmoid sinus:	0	4	2	0	2	0
subtentorial distribution	0	3	2	0	1	0
supratentorial distribution	0	0	0	0	0	0
sub- and supratentorial distribution	0	1	0	0	1	0
Confluence of sinuses:	5	0	0	0	0	0
subtentorial distribution	4	0	0	0	0	0
sub- and supratentorial distribution	1	0	0	0	0	0
Venous complications	0	0	0	1	0	1
Totality of resection:	12	13	3	4	7	3
total	0	0	0	1	1	2
subtotal						

Table 3. Surgical approaches, *n* (%)

Approach	Subtentorial meningiomas ( <i>n</i> = 27)	Supratentorial meningiomas ( <i>n</i> = 7)	Sub- and supratentorial meningiomas ( <i>n</i> = 12)
Paramedian suboccipital	12 (44.4)	0	4 (58.3)
Retrosigmoid	9 (33.3)	2 (28.5)	2 (16.6)
Median suboccipital	6 (22.3)	0	1 (8.4)
Posterior temporal craniotomy	0	0	1 (8.3)
Suboccipital	0	5 (71.5)	4 (8.4)
Tentoriotomy	3 (11.1)	1 (14.2)	11 (91.6)
Subtentorial approach	27 (100)	0	8 (66.7)
Supratentorial approach	0	7 (100)	4 (33.3)

In 16 cases with a medial tumor location, the paramedian suboccipital craniotomy was chosen, and the midline suboccipital craniotomy was performed in 7 cases.

The retrosigmoid craniotomy was used in 13 cases with lateral tumor location, the occipital craniotomy – in 9 patients with isolated supratentorial growth (5 cases) and with subsupratentorial growth (4 cases). In 1 patient with supra- and subtentorial tumor spread, the posterior temporal craniotomy was used. Tentoriotomy was performed in 15 cases to excise the growth zone on the tentorium cerebelli (Table 3). Intraoperatively, the temporary clipping of the transverse sinus was performed with an assessment of the degree and rate of brain herniation.

The transverse sinus was exposed distally and proximally from the tumor attachment zone and opened at the site of invasion, with the tumor removal from the central portion toward the intact portions of the sinus. Venous bleeding from the sinus was controlled by introducing the small fragments of hemostatic materials, which were

subsequently removed, and the sinus wall was reconstructed with a dural or periosteal flap and reinforced with fibrin glue. If reconstruction was impossible, the nondominant sinus was ligated. Microsurgical resection was performed using staged devascularization and fragmentation of the tumor with dissection of neurovascular structures. The dura mater in the area of meningioma growth, along with any remaining small fragments, was carefully coagulated.

Intraoperatively, the tumor location and attachment to the dura mater and sinus wall were determined, as well as its anatomical relationships with the cerebellum and vascular structures. The surgical approach included the resection of the intrasinus tumor component, taking into account the collateral venous drainage, sinus dominance, and the presence of blood flow within sinus lumen. In cases of partial sinus lumen occlusion and the absence of collateral drainage, the intrasinus component was not removed, and patients were subsequently referred for stereotactic radiosurgery.

Postoperatively, the neurological status was assessed as well as the computed tomography (CT) scans were performed for excluding the hemorrhagic and ischemic complications. The magnetic resonance imaging (MRI) was performed to determine the extent of tumor resection and residual deformation of neurovascular structures. In each patient, tumor morphology was confirmed by histological examination. The average follow-up period was 5 years and included an assessment of neurological status and brain contrast-enhanced MRI to rule out the continued tumor growth.

## RESULTS

According to magnetic resonance imaging (MRI), meningiomas appeared as rounded lesions with a broad base adjacent to the tentorium cerebelli, the transverse sinus, and, in some cases, the sigmoid sinus. The characteristic feature was the accumulation of contrast by the tumors and adjacent areas of the dura mater (Fig. 2).

In the examined series of cases, the average tumor size was 37.6 (11–79) mm, and occlusive hydrocephalus was detected in 5 patients. The tumor spread infratentorially in 27 cases, supratentorially – in 7 cases, and supra- and subtentorially – in 12 cases. Supratentorial spread was associated with basal occipital lobe deformity, while subtentorial spread was associated with cerebellar deformity, the severity of which depended on the tumor size.

The typical neurological manifestation was ataxia, observed in 36 cases (78.2 %). In 4 cases, cranial nerve damage was represented by dysfunction of the 5<sup>th</sup> nerve (hypesthesia) in 1 patient and dysfunction of the 8<sup>th</sup> nerve in 3 patients. Homonymous hemianopsia was observed in 1 patient (2.8 %), and decreased visual acuity in 7 patients (15.2 %). Preoperatively, the overall functional status according to the Karnofsky scale was 70 % in 14 patients, and 80–90 % in the remaining patients.

The total resection, corresponding to Simpson grade II, was performed in 42 patients, and subtotal tumor resection was done in 4 cases (Simpson grade III). According to histological examination results, the following meningioma types were identified: mixed – 15 cases (32.6 %), fibrous – 24 (52.2 %), transitional – 2 (4.3 %), meningotheliomatous – 3 (6.6 %), and psammomatous – 2 (4.3 %). The transverse sinus was ligated in 6 cases, its wall was reconstructed in 24 cases, and the wall of the initial part of the sigmoid sinus was reconstructed in 8 cases.

In the early postoperative period, ataxia regressed in 12 patients (33.3 %), and decrease of its severity was observed in 10 cases (27.7 %). Six patients experienced the onset or worsening of ataxic disturbances, and one patient with expressed supratentorial growth developed transient homonymous hemianopsia, which regressed after 2–3 weeks. Two patients developed cerebellar hemisphere venous infarction, manifested by severe ataxia, and

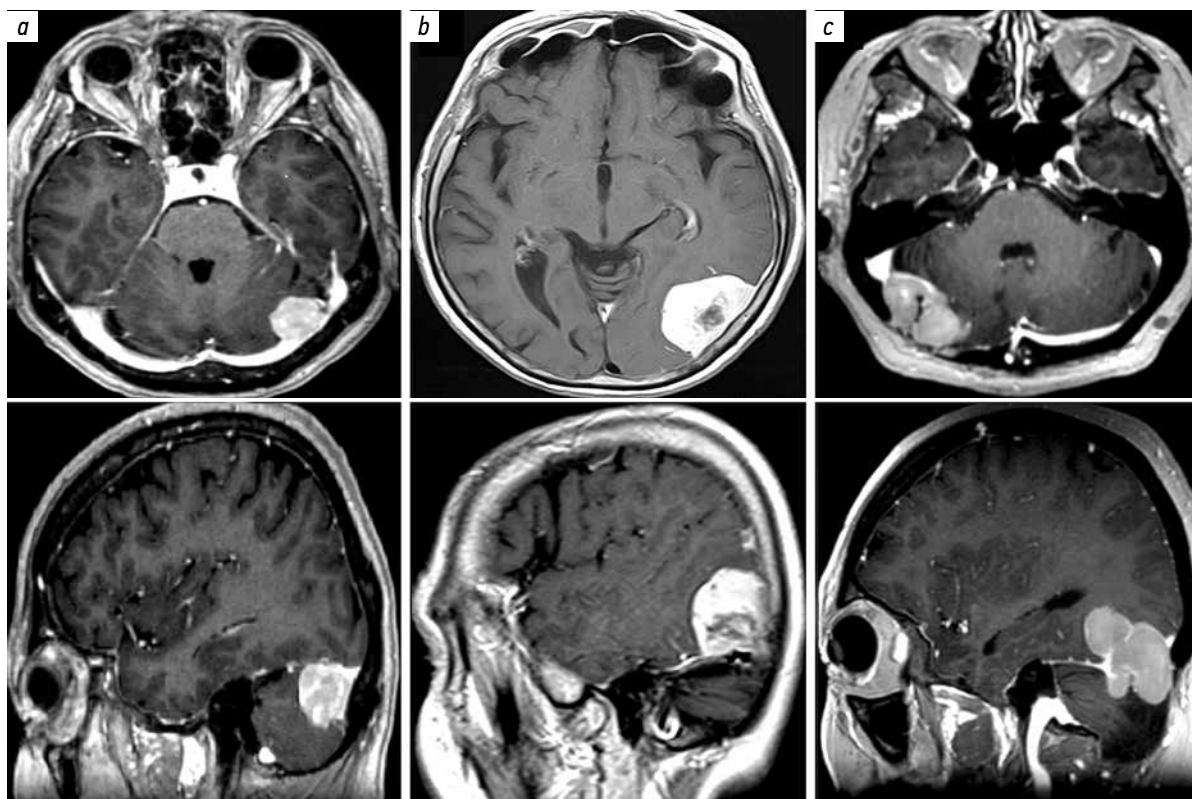


Fig. 2. Magnetic resonance imaging. Tentorial and transverse sinus meningiomas: a – subtentorial; b – supratentorial; c – sub- and supratentorial

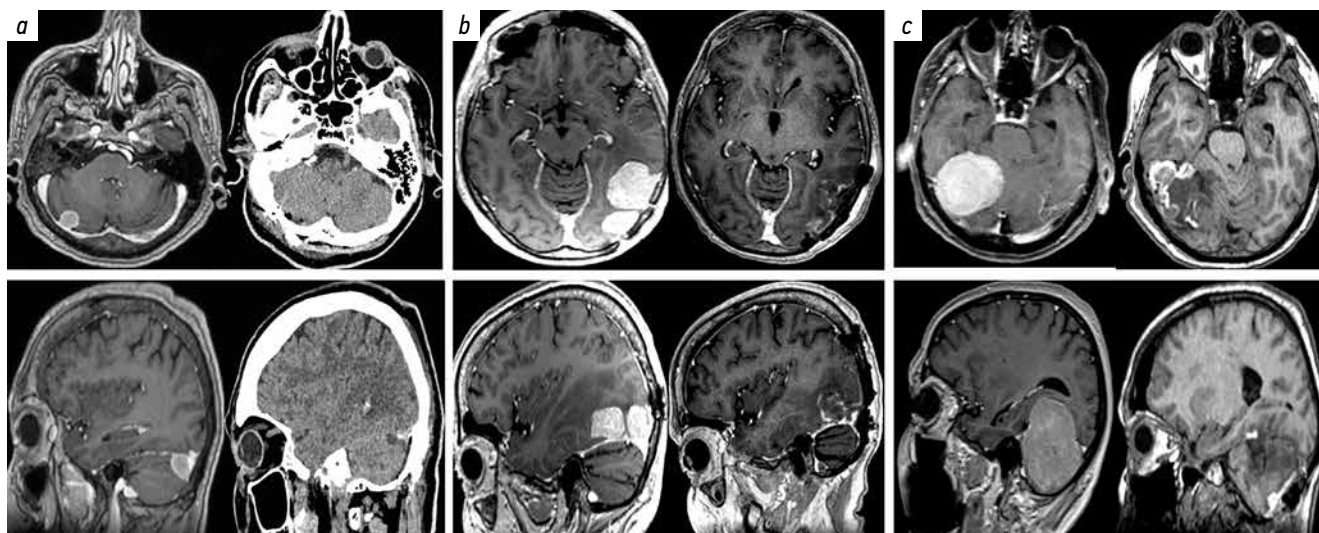


Fig. 3. Results of surgical treatment according to magnetic resonance imaging: a – subtentorial meningioma; b – supratentorial meningioma; c – sub- and supratentorial meningioma

conservative therapy resulted in regression of neurological symptoms.

In most patients, the non-focal cerebral symptoms regressed. The Karnofsky functional status score was 80–90 % in 41 patients, and 70 % in 5 patients. The follow-up revealed transient neurological impairments, which gradually regressed over 2–6 months. No postoperative infectious complications or fatal outcomes were recorded. The wound cerebrospinal fluid leakage was observed in 4 patients, successfully treated with external lumbar drainage.

The magnetic resonance imaging confirmed total tumor removal in 42 cases (91.3 %); in 4 cases (8.7 %) the contrast-enhancing small tumor remnants were detected in the transverse sinus, which prompted stereotactic radiosurgery (Fig. 3). The regression of hydrocephalus was observed in 4 of the 5 patients, and the degree of cerebellar dislocation was significantly reduced, although residual deformation of brain structures remained.

The follow-up revealed the continued tumor growth in five patients for four years after surgery. The stereotactic radiosurgery was performed in three cases, and repeated surgery was done in two cases.

## DISCUSSION

Meningiomas of the tentorium cerebelli and transverse sinus are accompanied by ataxia due to dislocation of the cerebellar hemisphere, and visual field impairment can be seen in case of tumor supratentorial spread with the compression of the occipital lobes.

An important aspect of TTSM surgical treatment is the degree of sinus invasion. It can be two types of meningioma removal – “conservative” and “aggressive” methods. The “conservative” method includes the separating of the tumor from the outer wall of the sinus and resecting the growth zone on the tentorium cerebelli. The intrasinus

component is not removed, and collateral veins are preserved, while the remaining tumor is treated with stereotactic radiosurgery. The “aggressive” method includes the additional resection of the intrasinus component with sinus ligation or reconstruction of the sinus wall.

The removal of the intrasinus component reduces the risk of recurrence but it is associated with increased neurological deficit due to impaired venous outflow [6, 7]. The criteria for selecting the aggressive approach include the complete occlusion of the sinus lumen revealing by venography as well as the partial occlusion of the nondominant sinus with a negative intraoperative clip test, and the absence of tumor invasion of the sinus wall. In other cases, the conservative surgical approach is used.

For a preliminary intraoperative assessment of the drainage type and the outcome of sinus ligation, temporary clipping test for 30 minutes is recommended, with an assessment of the degree of brain herniation. According to the classification of venous drainage by S.K. Hwang et al. [5], epy sinus ligation is possible for types A, B, and C if temporary sinus clipping test fails.

For type I invasion, M. Sindou and P. Hallacq recommend the total tumor removal by dissection from the outer sinus wall. For types II–IV invasion, the tumor is removed along with the sinus wall to increase the degree of radicality and reduce the risk of recurrence. The wall defect is repaired using dura mater, fascia, synthetic material, suturing of a muscle fragment, or the use of a hemostatic sponge.

In cases of tumor invasion into the dominant sinus or partial sinus occlusion, the coagulation of the meningioma growth zone followed by stereotactic radiosurgery is recommended. In cases of complete sinus occlusion (types V–VI) and the absence of blood flow based on venography, the sinus is ligated proximally and distally from the occlusion site, and the tumor is removed along with

the affected sinus. In cases of extensive tumor occlusion, the transverse sinus is ligated near the superior petrosal sinus, preserving the orifice of the Labbe vein.

The safe radical resection is only possible for type I sinus invasion. Invasion of the initial portions of the sigmoid sinus in our study did not require changes in surgical tactics. In cases of superior petrosal sinus invasion, the intraluminal component was removed followed by tamponade with hemostatic material or sinus wall grafting. In cases of vein Labbe orifice invasion, the intraluminal fragment was not resected, and stereotactic radiosurgery was performed.

The total occlusion of the venous sinus in the absence of collateral venous outflow leads to local regional venous hypertension [8, 9]. The postoperative venous infarctions occur even with marginal tumor invasion after sinus wall plasty [10, 11]. The risk of venous infarction is reduced by preserving large draining veins, which provide collateral venous circulation in the presence of complete sinus occlusion [4, 10, 12].

The revascularization of the transverse and sigmoid sinuses is used in cases of complete occlusion or the necessity for sinus ligation, and the technique is selected based on the results of intrasinus pressure measurements during an occlusion test [8, 13, 14, 20]. The internal saphenous vein, radial artery, or synthetic materials are used as grafts [8, 13, 15–20].

## CONCLUSION

The typical neurological manifestation of TTSM is ataxia, and less commonly, homonymous hemianopsia. The surgical treatment depends on the degree of transverse sinus occlusion. The surgical approach should ensure complete visualization of the affected sinus area, and the choice of a supra- or infratentorial approach is determined by the tumor predominant extent. The goal of surgical interventions for transverse sinus occlusion is maximal tumor resection while preserving venous outflow through the sinuses and collateral veins, which ensures the preservation of cerebral structures and minimizes the risk of neurological complications.

## References

- Abbassy M., Woodard T.D., Sindwani R., Recinos P.F. An overview of anterior skull base meningiomas and the endoscopic endonasal approach. *Otolaryngol Clin North Am* 2016;49(1):141–52. DOI: 10.1016/j.otc.2015.08.002
- Bassiouni H., Hunold A., Asgari S., Stolke D. Tentorial meningiomas: clinical results in 81 patients treated microsurgically. *Neurosurgery* 2004;55(1):108–16. DOI: 10.1227/01.neu.0000126886.48372.49
- Ehresman J.S., Mampre D., Rogers D. et al. Volumetric tumor growth rates of meningiomas involving the intracranial venous sinuses. *Acta Neurochir (Wien)* 2018;160(8):1531–8. DOI: 10.1007/s00701-018-3571-3
- Sindou M., Hallacq P. Venous reconstruction in surgery of meningiomas invading the sagittal and transverse sinuses. *Skull Base Surg* 1998;8(2):57–64. DOI: 10.1055/s-2008-1058576
- Hwang S.K., Gwak H.S., Paek S.H. et al. Guidelines for the ligation of the sigmoid or transverse sinus during large petroclival meningioma surgery. *Skull Base* 2004;14(1):21–8; discussion 29. DOI: 10.1055/s-2004-821356
- Castellano F., Ruggiero G. Meningiomas of the posterior fossa. *Acta Radiol Suppl* 1953;104:1–177. DOI: 10.1177/0284185153039S10405
- Mantovani A., Di Maio S., Ferreira M.J., Sekhar L.N. Management of meningiomas invading the major dural venous sinuses: operative technique, results, and potential benefit for higher grade tumors. *World Neurosurg* 2014;82(3–4):455–67. DOI: 10.1016/j.wneu.2013.06.024
- Sindou M.P., Alvernia J.E. Results of attempted radical tumor removal and venous repair in 100 consecutive meningiomas involving the major dural sinuses. *J Neurosurg* 2006;105(4):514–25. DOI: 10.3171/jns.2006.105.4.514
- Mazur M.D., Cutler A., Couldwell W.T., Taussky P. Management of meningiomas involving the transverse or sigmoid sinus. *Neurosurg Focus* 2013;35(6):E9. DOI: 10.3171/2013.8.FOCUS13340
- Jang W.Y., Jung S., Jung T.Y. et al. Predictive factors related to symptomatic venous infarction after meningioma surgery. *Br J Neurosurg* 2012;26(5):705–9. DOI: 10.3109/02688697.2012.690914
- Sughrue M.E., Rutkowski M.J., Shangari G. et al. Incidence, risk factors, and outcome of venous infarction after meningioma surgery in 705 patients. *J Clin Neurosci* 2011;18(5):628–32. DOI: 10.1016/j.jocn.2010.10.001
- Sindou M. Meningiomas invading the sagittal or transverse sinuses, resection with venous reconstruction. *J Clin Neurosci* 2001;8(Suppl 1):8–11. DOI: 10.1054/jocn.2001.0868
- Orlov E.A., Polunina N.A. Cerebral venous revascularization in meningioma surgery. *Neyrokhirurgiya = Russian Journal of Neurosurgery* 2023;25(2):130–9. (In Russ.). DOI: 10.17650/1683-3295-2023-25-2-130-139
- Ehresman J.S., Mampre D., Rogers D. et al. Volumetric tumor growth rates of meningiomas involving the intracranial venous sinuses. *Acta Neurochir (Wien)* 2018;160(8):1531–8. DOI: 10.1007/s00701-018-3571-3
- Debernardi A., Quilici L., La Camera A. et al. Torcular meningioma with multi-venous sinus invasion: compensatory drainage veins and surgical strategy. *World Neurosurg* 2018;109:451–4. DOI: 10.1016/j.wneu.2017.10.120
- Nagashima H., Kobayashi S., Takemae T., Tanaka Y. Total resection of torcular herophili hemangiopericytoma with radial artery graft: case report. *J Neurosurgery* 1995;36(5):1024–7. DOI: 10.1227/00006123-199505000-00022
- Bederson J.B., Eisenberg M.B. Resection and replacement of the superior sagittal sinus for treatment of a parasagittal meningioma: technical case report. *Neurosurgery* 1995;37(5):1015–8; discussion 1018–9. DOI: 10.1227/00006123-199511000-00026
- Hakuba A. Reconstruction of dural sinus involved in meningioma. In: *Meningiomas*. Ed. by O. Al-Mefty. New York: Raven Press 1991. Pp. 371–382.
- Hakuba A., Huh C.W., Tsujikawa S., Nishimura S. Total removal of a parasagittal meningioma of the posterior third of the sagittal sinus and its repair by autologous vein graft. Case report. *J Neurosurg* 1979;51:379–82. DOI: 10.3171/jns.1979.51.3.0379
- Sindou M., Mercier P., Bokor J., Brunon J. Bilateral thrombosis of the transverse sinuses: microsurgical revascularization with venous bypass. *Surg Neurol* 1980;13(3):215–20.

**Authors' contributions**

D.A. Kulichkov: data collection and analysis, statistical analysis, article writing;  
G.Y. Grigoryan: research design development, data interpretation, editing of the article;  
O.N. Dreval, Y.A. Grigoryan: scientific consulting, scientific editing.

**ORCID of authors**

D.A. Kulichkov: <https://orcid.org/0009-0007-6144-1108>  
G.Y. Grigoryan: <https://orcid.org/0000-0001-5745-8061>  
O.N. Dreval: <https://orcid.org/0000-0002-8944-9837>  
Y.A. Grigoryan: <https://orcid.org/0000-0003-3157-6187>

**Conflict of interest.** The authors declare no conflict of interest.

**Funding.** The study was performed without external funding.

**Compliance with patient rights and principles of bioethics.** The study protocol was approved by the local ethics committee of the Russian Medical Academy of Continuous Professional Education of the Ministry of Health of Russia. The study was retrospective.